

**DIAGNOSTIC CHALLENGE**

**A swimmer's wheeze**

Brian Deady, MD;\* James Glezos, MD;† Stephen Blackie, MD†

**Case history**

A previously healthy 38-year-old triathlete prepared for a swim in a cold (15°C) lake by drinking 1/2 L of a protein supplement and putting on a wetsuit. After swimming approximately 500 m, she developed dyspnea. She stopped momentarily and then continued on, but developed further dyspnea associated with chest constriction and wheezing. Her exercise tolerance deteriorated dramatically, such that she had to be towed to shore by another swimmer. Throughout the swim and rescue procedure her head was not submerged and she did not aspirate lake water.

Upon reaching the shore, the patient's symptoms continued, and she also developed hemoptysis. Nevertheless, she was able to drive herself to the the emergency department at the nearest hospital, 15 minutes away.

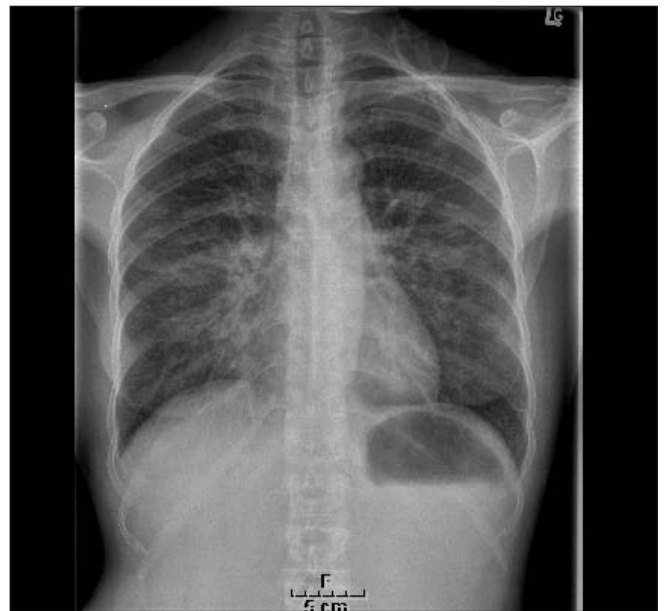
In the emergency department, the patient was found to be in moderate respiratory distress, tachypneic, able to speak only in brief phrases, and profoundly hypoxemic (blood pressure = 119/72 mm Hg; heart rate = 72 beats/min; respiratory rate = 32 breaths/min; SaO<sub>2</sub> = 72% on room air). There was no jugular venous distension, no cardiac murmurs or gallops, and no dependent edema, but there was diffuse wheezing on auscultation of the chest.

Laboratory investigations showed borderline elevation of the D-dimer, but results of troponin I tests and the ECG were normal. The initial sitting anterior–posterior chest x-ray is shown in Figure 1.

This patient's most likely diagnosis is:

- a) food-associated exercise-induced anaphylaxis;
- b) cold urticaria;
- c) swimming-induced pulmonary edema; or
- d) cardiogenic pulmonary edema.

**For the Answer to this Challenge, see page 297.**



**Fig. 1. Results of the initial sitting anterior–posterior chest x-ray**

From the \*Emergency Department, and the †Division of Respiratory and Critical Care Medicine, Royal Columbian Hospital, New Westminster, BC

Received: Jan. 4, 2006; accepted: Jan. 30, 2006

*This article has been peer reviewed.*

*Can J Emerg Med 2006;8(4):281*