

Atraumatic hemopericardium in a patient receiving warfarin therapy for a pulmonary embolus

Peter G. Katis, MD

ABSTRACT

Acute pericardial tamponade is a potentially life-threatening condition that requires immediate treatment. This report describes a patient who presented to the emergency department with an acute hemopericardium and echocardiographic evidence of cardiac tamponade following the initiation of warfarin therapy for a recently diagnosed pulmonary embolism. The association between cardiac tamponade, oral anticoagulation and pulmonary thromboembolic disease is briefly discussed.

Key words: cardiac tamponade; oral anticoagulants; pulmonary embolism; hemopericardium

RÉSUMÉ

La tamponnade péricardique aiguë est une atteinte menaçante pour la vie qui nécessite un traitement immédiat. Le présent article décrit le cas d'un patient reçu à l'urgence pour un hémopéricarde aigu et des signes échocardiographiques de tamponnade cardiaque à la suite du début d'un traitement à la warfarine pour une embolie pulmonaire diagnostiquée récemment. L'association entre la tamponnade cardiaque, l'anticoagulation orale et la maladie thromboembolique pulmonaire est discutée brièvement.

Introduction

Acute pericardial tamponade is a potentially life-threatening condition that may result when fluid accumulates in the intrapericardial space.¹ The fluid may arise from traumatic causes (e.g., hemorrhage after penetrating injury) or atraumatic causes such as malignancy, infection or uremia.² As fluid accumulates in the pericardium, pericardial pressure increases and may exceed right heart filling pressures and mechanically restrict right heart filling.² This phenomenon decreases stroke volume and compromises cardiac output.^{1,2} Patients with acute pericardial tamponade may initially be hemodynamically stable but can deteriorate within minutes

if appropriate treatment is not initiated.¹ Treatment consists of supportive measures such as volume expansion to aid with right heart filling and more definitive measures such as pericardiocentesis, which can also aid in diagnosis.²

This paper reports the case of a patient who presented to the emergency department (ED) with cardiac tamponade secondary to atraumatic hemopericardium following the initiation of warfarin therapy for a recently diagnosed pulmonary embolism (PE).

Case report

A 67-year-old woman presented to the ED with severe

Interim Medical Director, Emergency Medicine, University Health Network, Toronto, Ont., and Lecturer, Department of Family and Community Medicine, University of Toronto, Toronto

Received: Nov. 24, 2004; final submission: Feb. 1, 2005; accepted: Feb. 5, 2005.

This article has been peer reviewed.

Can J Emerg Med 2005;7(3):168-70

chest pain that began suddenly the previous evening while at rest. The pain was “sharp,” radiated to her shoulders and neck, and was accompanied by dyspnea. There were no relieving or aggravating factors. Three weeks prior to her visit, and 4 days after a left knee arthroplasty, she had presented with similar symptoms, at which time a CT study demonstrated PE. Hematologic testing for thrombophilia, and bilateral leg Doppler ultrasonography for deep venous thrombosis were negative. Her current pain differed from her previous in that it was non-pleuritic and more severe.

Her past medical history was significant for hypertension and hypercholesterolemia. She had no other cardiac risk factors, no history of coronary artery disease, and no history of malignancy. She had been taking warfarin, 5 mg daily, since the diagnosis of her PE, but optimization of her international normalized ratio (INR) had been difficult to achieve, with levels fluctuating between 2 and 6. In addition to warfarin, her medications included amlodipine, perindopril, simvastatin and lorazepam.

On examination, the patient was in severe distress secondary to chest pain, with vital signs as follows: temperature 36.4°C, blood pressure 150/80 mm Hg (equal in both arms and with an absence of pulsus paradoxus), heart rate 94 beats/min, respiratory rate 24 breaths/min and oxygen saturation 94% on room air. The cardiac examination was remarkable for faint heart sounds but no murmurs, rubs or thrills could be appreciated. Jugular venous pressure could not be ascertained secondary to redundancy of neck tissue. Findings on respiratory, abdominal and peripheral vascular examinations were unremarkable.

Her hemoglobin had dropped to 85 g/L from 111 g/L on her previous visit. Her INR was 3.51. All other blood work, including white cell count, platelets, electrolytes, glucose, creatinine, liver enzymes, amylase, PTT [partial thromboplastin time] and troponin were within normal limits. An ECG showed normal sinus rhythm with normal QRS amplitude and no signs of right heart strain or ischemia. A contrast CT scan of the chest demonstrated a large circumferential pericardial effusion that was not present previously (Fig. 1). Signs of her previous acute pulmonary thromboembolic disease had largely resolved, save for the presence of residual linear filling defects and a small right pleural effusion. No structural cause for the pericardial fluid was appreciated, and the great vessels and thoracic lymph nodes appeared normal.

Given the CT findings and the documented decrease in hemoglobin level, the patient was treated for a presumed hemopericardium with intravenous vitamin K and fresh frozen plasma in order to reverse her anticoagulated state. A bedside echocardiogram confirmed the presence of a large peri-

cardial effusion and additionally revealed sustained right atrium inversion and right ventricular diastolic collapse (findings suggestive of cardiac tamponade). The patient underwent pericardiocentesis, which yielded 400 cc of blood and relieved her symptoms. A pericardial drain was placed, and samples were sent for culture, cytology and acid-fast bacilli testing. These studies were ultimately negative.

Serial echocardiograms while in hospital demonstrated resolution of the effusion. The pericardial drain was removed on the third day of admission after having yielded a total of 600 cc of blood. Given the patient's risk for thromboembolic disease, an intravenous heparin drip had been started. Unfractionated heparin was eventually discontinued in favour of subcutaneous enoxaparin injections. The patient was discharged and followed closely as an outpatient in the thrombosis clinic while receiving her enoxaparin injections through arrangements made with home care. She continues to do well after several months of follow-up and has not had a recurrence of chest pain or dyspnea.

Discussion

This case report describes a woman who developed a delayed atraumatic hemopericardium with echocardiographic evidence of cardiac tamponade while taking warfarin for pulmonary thromboembolic disease. A search of the medical literature from 1966 onward reveals isolated reports of delayed cardiac tamponade occurring in patients taking an-

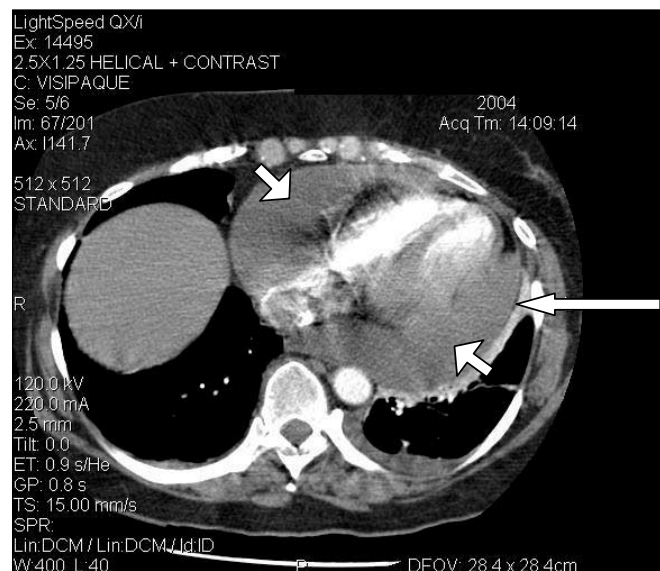


Fig. 1. Results of CT of the thorax, performed on the patient at time of presentation. Two short white arrows = large circumferential pericardial effusion; one long white arrow = interface between pericardium and hemopericardium.

ticoagulant therapy after cardiac instrumentation or surgery (for example, valve or coronary artery bypass surgery).^{3,4} In these reports there was a tendency toward large intrapericardial collections of blood and for overt tamponade when anticoagulation was excessive.^{3,4} We also found a single report of a 67-year-old man who developed atraumatic hemopericardium and cardiac tamponade while receiving warfarin therapy for the treatment of vertebral-basilar artery insufficiency.⁵ Following diagnosis and management, this patient was discharged home without resuming warfarin therapy and reportedly continued to do well.

The occurrence of pulmonary embolism and cardiac tamponade secondary to hemopericardium has also been observed in the literature, but the 2 reports that describe this phenomenon have described the simultaneous existence of the 2 conditions.^{6,7} Finally, there has also been a single case report of cardiac tamponade secondary to hemopericardium following streptokinase therapy for pulmonary embolism.⁸

Conclusion


This is the first report of a delayed atraumatic hemopericardium with echocardiographic evidence of cardiac tamponade in a patient receiving warfarin therapy for treatment of pulmonary thromboembolic disease. In this patient other causes for hemopericardium were effectively excluded, as was the possibility that the hemopericardium developed prior to anticoagulation. Poor anticoagulation control may have contributed to the development of the hemopericardium. Emergency physicians should remember that warfarin therapy is not without risks, and that strict control of target INRs should be the goal for patients on this therapy.

Competing interests: None declared.

References

1. Eckstein M, Henderson S, Markovchick V. Thorax. In: Marx JA, Hockberger RS, Walls RM, editors. Rosen's Emergency Medicine: concepts and clinical practice, 5th ed. St. Louis: Mosby; 2002. p. 381-414.
2. Niemann JT. The cardiomyopathies, myocarditis, and pericardial disease. In: Tintinalli JE, Kelen GD, Sapsczynski JS, editors. Emergency medicine: a comprehensive study guide, 6th ed. New York: McGraw-Hill; 2004. p. 378-86.
3. Mangi AA, Palacios IF, Torchiana DF. Catheter pericardiocentesis for delayed tamponade after cardiac valve operation. *Ann Thorac Surg* 2002;73(5):1479-83.
4. Malouf JF, Alam S, Gharzeddine W, Stefadouros MA. The role of anticoagulation in the development of pericardial effusion and late tamponade after cardiac surgery [published erratum appears in *Eur Heart J* 1994;15(4):583-4]. *Eur Heart J* 1993; 14(11):1451-7.
5. Lee KS, Marwick T. Hemopericardium and cardiac tamponade associated with warfarin therapy. *Cleve Clin J Med* 1993;60(4): 336-8.
6. Nguyen Ba V, Debien B, Villevieille T, Quiniou G, Pollet L, Lenoir B, et al. [Pulmonary embolism to the rescue in cardiac tamponade.] *Ann Fr Anesth Reanim* 2003;22(10):896-9.
7. Jairath UC, Benotti JR, Spodick DH. Cardiac tamponade masking pulmonary embolism [review]. *Clin Cardiol* 2001;24(6): 485-6.
8. Giles PJ, D'Cruz IA, Killam HA. Tamponade due to hemopericardium after streptokinase therapy for pulmonary embolism. *South Med J* 1988;81(7):912-4.

Correspondence to: Dr. Peter Katis, Toronto General Hospital, R Fraser Elliot Building, GS-434, 200 Elizabeth St., Toronto ON M5G 2C4; 416 340-3856, fax 416 340-4300, peter.katis@uhn.on.ca




CARE STATIONS
FOR WAITING ROOMS / EXAM ROOMS

Please ask us how to get a free sample for trial

**Get to see more patients
Spend less, smarter for your practice**

EFFICIENCY SOLUTIONS
HEALTH CARE PRACTICES TODAY / ENHANCED EFFICIENCY



General practice consulting

Alcoholism

Special diets

Drug addiction

Personal development

Chronic-care planning

HRIS consultation

Private and Home

Databases

Point-of-care

Quality Care-Line

Work or Online

Work, Home, or Car

*There's a solution
to connect office desktops
into Care Stations*

*Please request please contact
(416) 329-2222 ext 200*

MECHAMILLUM

www.care-stations.ca