

## Answer

Michael Wansbrough, MD, MSc (Epi), DTM&H, DLSHTM

The best answer is “C”: verify the quality of radial pulses. But in this case, because of the likelihood of occult injury with a large stab wound, a chest CT was ordered. After reviewing the plain films, the radiologist was hesitant to proceed, and a surgical consult was obtained. The surgeon found the left radial pulse to be slightly diminished compared to the right and obtained a CT chest with contrast. The CT demonstrated a hematoma surrounding the left subclavian artery.

The patient was transferred to a trauma centre, where he underwent angiography of the aortic arch and left subclavian artery. This demonstrated a pseudoaneurysm of the subclavian artery and a fistula between the artery and vein with a significant amount of blood being shunted from the artery to the vein. Although his distal vessels appeared normal, there was a slightly decreased blood flow due to the arteriovenous shunt. Because the artery was patent and the patient stable, operative repair was deferred until the next morning.

### Discussion

In this case, the knife blade traveled under the clavicle and

into the subclavian artery without traversing the pleural membrane.

Subclavian artery injuries represent 1% to 2% of all vascular trauma, 95%–99% of which result from penetrating trauma.<sup>1</sup> Most patients die from massive hemorrhage in the field, and the remainder tend to present in shock.<sup>2,3</sup> More than half of the injuries are associated with hemo-

**... in cases of proximal arterial disruption [brachial or radial] pulses are absent in only one-third of cases because of collateral flow from the thyrocervical trunk.**

pneumothorax and injury to mediastinal, and spinal structures are common.<sup>1</sup> Subclavian vein injuries are two times more lethal than arterial injuries. This may be due to the combination of massive blood loss and a high risk of air embolism.<sup>3</sup> It is important to carefully check brachial or ra-

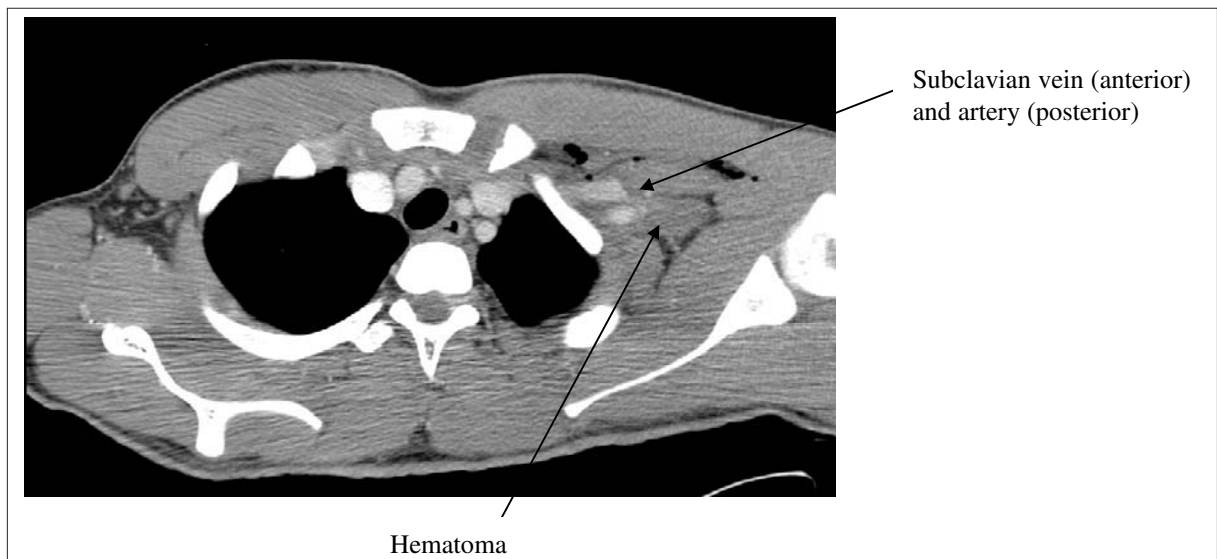


Fig. 1. CT of the chest demonstrating extrapleural hematoma adjacent to the subclavian artery.

dial pulses, but in cases of proximal arterial disruption these pulses are absent in only one-third of cases because of collateral flow from the thyrocervical trunk. Upper extremity neurological deficits are found in slightly more than half of patients, the majority related to brachial plexus injury.<sup>4</sup>

Definitive diagnosis is made by angiography because overlying air-filled lungs often preclude ultrasound visualization and the sensitivity of the ABI (ankle brachial index) is affected by collateral blood flow. One retrospective study of 100 patients with periclavicular trauma found that a normal physical exam coupled with a normal chest x-ray eliminated the need for angiography and would not have missed any vascular injuries.<sup>5</sup> Treatment is surgical in the majority of cases.

This case demonstrates the importance of a careful physical exam and reassessment. In particular, it shows that the presence of a pulse does not rule out vascular injury and that comparison with the contralateral pulse is critical.

**Competing interests:** None declared.

## References

1. Cox CS, Allen GS, Fischer RP, Conklin LD, Duke JH, Co-canour CS, et al. Blunt versus penetrating subclavian artery injury: presentation, injury pattern, and outcome. *J Trauma* 1999;46:445-9.
2. McKinley AG, Carrim AT, Robbs JV. Management of proximal axillary and subclavian artery injuries. *Br J Surg* 2000;87:79-85.
3. Demetriades D, Chahwan S, Gomez H, Peng R, Velmahos G, Murray J, et al. Penetrating injuries to the subclavian and axillary vessels. *J Am Coll Surg* 1999;188:290-5.
4. Demetriades D, Asensio JA. Subclavian vascular injuries. *Br J Surg* 1987;74:1001-3.
5. Gasparri MG, Lorelli DR, Kralovich KA, Patton JH Jr. Physical examination plus chest radiography in penetrating periclavicular trauma: the appropriate trigger for angiography. *J Trauma* 2000;49:1029-33.

**For the Question, see page 56.**

---

**Correspondence to:** Dr. Michael Wansbrough, 5 – 62 Claremont St., Toronto ON M6J 2M5; 416 203-2360, fax 416 203-2502, mwansbrough@sympatico.ca