

Use of telemedicine in the management of life-threatening periorbital necrotizing fasciitis in a remote community

Parsa Mehraban Far, BHSc*; Jacob Rullo, MD, PhD*; Vladimir Kratky, MD, FRCSC, DABO*

Keywords: Necrotizing fasciitis, ophthalmology, rural medicine, surgical debridement

CASE PRESENTATION

A 51-year-old female presented to a rural emergency room with a 12-hour history of progressive left orbital swelling, pain, and malaise. There was no history of antecedent trauma, previous illness, or infectious contacts. Her past medical history includes a history of systemic lupus erythematosus currently managed with Plaquenil. On examination, she was febrile with a temperature of 39.2° C. Remaining vitals were within normal limits. Assessment of the left eye and orbit was not possible given the extensive eyelid swelling. Computed tomography (CT) and magnetic resonance imaging (MRI) scans were unavailable to the ordering physician in order to rule out an orbital cellulitis. Digital anonymized photographs were sent to the ophthalmology resident on call to aid diagnosis as the patient was located 7.5 hours by plane from the closest acute care hospital (Figure 1A).

The patient was started on ceftriaxone. Arrangements were made to send the patient to the local acute care hospital for admission to the emergency ophthalmology service via air-ambulance to rule out an orbital infectious process. Two hours later, the physician contacted the ophthalmology resident with the following information: Patient's temperature, 39.2° C; pulse, 100–110; blood pressure, 98/59; and white blood cell count, 19 10⁹/L. The descriptions were concerning for an aggressive

necrotizing process. The patient was started on intravenous fluids. Intravenous antibiotics were broadened to piperacillin and tazobactam, and the plan was for admission to the intensive care unit upon arrival for stabilization and urgent ophthalmology assessment.

Upon arrival, the patient was stabilized by the critical care team and continued on intravenous piperacillin with tazobactam, vancomycin, and clindamycin. Initial ophthalmic examination showed a tender, erythematous, bullous upper eyelid with associated bilateral edema and necrosis worse on the left. Upper eyelid sensation was decreased. Routine laboratory tests showed a hemoglobin of 91 g/L, white blood cell count of 21 10⁹/L, and a C-reactive protein of 165 mg/L.

She was diagnosed with presumed periorbital necrotizing fasciitis given the evolution and appearance of the periorbital region, namely, changes in skin colour and skin breakdown. She underwent urgent extensive debridement of necrotic tissue by our oculoplastic service (see Figure 1B). Histopathology demonstrated acute liquefactive necrosis with the presence of gram-positive cocci. Cultures were positive for *Streptococcus pyogenes*. Her presentation of fever and hemodynamic instability likely represented early *Streptococcal* toxic shock syndrome. Her clinical condition improved post-debridement with the development of healthy granulation tissue at the wound (see Figure 1C-D). She was eventually discharged on oral cefprozil and made a good recovery with an excellent cosmetic result with no further intervention. We obtained verbal consent for the publication of this report at the time of patient discharge.

From the *Department of Ophthalmology, Queen's University, Hotel Dieu Hospital, Kingston, ON.

Correspondence to: Dr. Vladimir Kratky, Queen's University, Department of Ophthalmology, 166 Brock Street, Kingston, ON K7L 5G2; Email: kratkyv@gmail.com

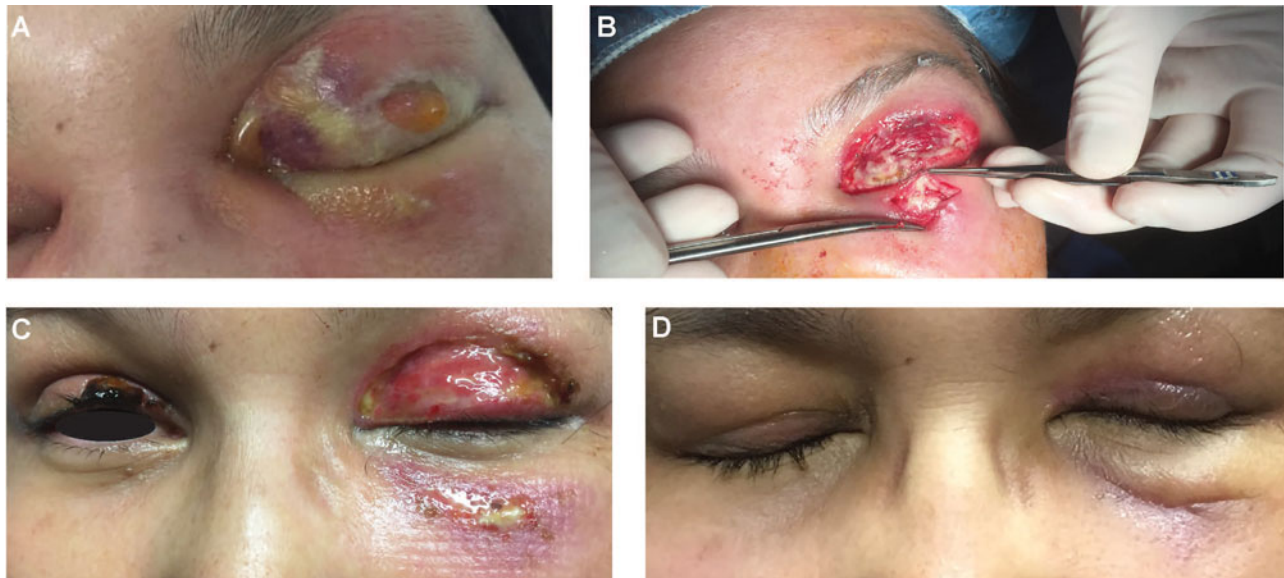


Figure 1. Surgical debridement of necrotic tissues in periorbital necrotizing fasciitis. (A) Digital image that was sent by the caring physician to the ophthalmology resident on call for consultation. (B) Urgent surgical debridement of infected tissues on the left eye. (C) Growth of healthy granulation tissue over the wound 2 weeks after the surgical debridement. (D) Full recovery of the left eye 6 months after the surgery.

DISCUSSION

Necrotizing fasciitis is a life-threatening infection of subcutaneous tissue and superficial fascia with secondary necrotic involvement of the overlying skin.¹ Decades after its first description, early diagnosis of necrotizing fasciitis remains challenging; death due to septic shock syndrome remains relatively high; and patients face long-term debility.¹ In rare cases, necrotizing fasciitis can affect the soft tissue surrounding the eye, presenting as periorbital necrotizing fasciitis.¹

The clinical course of periorbital necrotizing fasciitis is rapid, with acute painful periorbital swelling progressing to violaceous, bullous gangrene and necrosis within hours.¹ Depending on the urgency of its presentation, treatment usually involves emergency surgical debridement with high-dose penicillin and clindamycin treatment.² The literature around periorbital necrotizing fasciitis is isolated to case reports, with little synthesized evidence available to provide a strong foundation for diagnosis and management of these patients to emergency physicians. We believe that our case and its management demonstrate several clinical pearls for clinicians when dealing with patients presenting remotely for a soft tissue infection around the eye.

Firstly, a grading scale has been developed to help differentiate necrotizing fasciitis from other soft tissue

infections.³ This scale uses six laboratory variables, including white blood cell count, hemoglobin, sodium, glucose, creatinine and C-reactive protein, with a maximum of 13 attainable points.³ A score of 6 or more points carries a positive predictive value of 92% and a negative predictive value of 96% for a diagnosis of necrotizing fasciitis.³ Upon admission to the hospital, the patient described in this report scored 8 and was immediately treated for periorbital necrotizing fasciitis. This scoring system could be particularly useful to physicians in rural settings where rapid and early decisions can be life-saving.

Secondly, our case demonstrates the emergent nature of non-surgical interventions for periorbital necrotizing fasciitis.⁴ In the recent years, there has been a push towards minimizing surgical interventions for periorbital necrotizing fasciitis due to possibilities of disfigurement and relying on high-dose antibiotic therapy alone.⁴ Although these reports are promising, the current standard of care for moderate-to-severe periorbital necrotizing fasciitis still remains surgical debridement of necrotic areas due to the possibility of inadequate drug distribution secondary to low perfusion of infected tissues.¹ In this case, the patient presented with bilateral infection worse on the left side. The surgeon made the decision to operate on the left side and treated the right side conservatively using antibiotics. Future studies

are required to objectively evaluate any benefits and harms associated with surgical co-intervention of mild periorbital necrotizing fasciitis to assist guideline development for this complex medical entity.

Thirdly, this case demonstrates that teleophthalmology could have a special place in emergency medicine. A large proportion of emergency department (ED) visits are due to ocular diseases. In the United States, for instance, there are approximately 2 million ED visits requiring ophthalmic examination per year, despite over 50% of EDs not having eye care professionals.⁵ In this case, the ophthalmology team's decision to transfer the patient was influenced by access to patient images (see [Figure 1A](#)). Moreover, the advent of fundus photography, which allows for a simple means to obtaining posterior segment imaging, combined with high-speed transfer of images over secure networks, can lead to a rise in popularity of teleophthalmology in emergency medicine. Further development of teleophthalmology programs could assist primary healthcare providers tasked with providing best care to patients with

challenging ophthalmic diseases and improve the health of Canadians.

Competing interests: None declared.

REFERENCES

1. Amrith S, Hosdurga Pai V, Ling WW. Periorbital necrotizing fasciitis – a review. *Acta Ophthalmol* 2013;91(7):596–603.
2. Franzen D, Butsch R, Chaloupka K. Appearances are deceptive.... *BMJ Case Reports*. 2013; epub, doi:10.1136/bcr-2013-009315.
3. Wong CH. The LRINEC (Laboratory Risk Indicator for Necrotizing Fasciitis) score: a tool for distinguishing necrotizing fasciitis from other soft tissue infections. *Crit Care Med* 2004;32:1535–41.
4. Hooi LL, Hou BA, Leng SL. Group A Streptococcus necrotizing fasciitis of the eyelid: a case report of good outcome with medical management. *Ophthalmic Plast Reconstr Surg* 2012;28(1):e13–5.
5. Rathi S, Tsui E, Mehta N, Zahid S, Schuman JS. The current state of teleophthalmology in the United States. *Ophthalmology* 2017;124(12):1729–34.