

International Federation for Emergency Medicine Consensus Statement: Sonography in hypotension and cardiac arrest (SHoC): An international consensus on the use of point of care ultrasound for undifferentiated hypotension and during cardiac arrest

Paul Atkinson, MB, MA*[†]; Justin Bowra, MB^{‡§}; James Milne, MD[¶]; David Lewis, MB*[†]; Mike Lambert, MD**[†]; Bob Jarman, MB, MSc^{††‡‡§§}; Vicki E. Noble, MD^{§§¶¶}; Hein Lamprecht, MB***[†]; Tim Harris, BM^{††††‡‡§§}; Jim Connolly, MB^{††}

and members of the International Federation of Emergency Medicine Sonography in Hypotension and Cardiac Arrest working group: Romolo Gaspari, MD, PhD; Ross Kessler, MD; Christopher Raio, MD; Paul Sierzenski, MD; Beatrice Hoffmann, MD; Chau Pham, MD; Michael Woo, MD; Paul Olszynski, MD; Ryan Henneberry, MD; Oron Frenkel, MD; Jordan Chenkin, MD; Greg Hall, MD; Louise Rang, MD; Maxime Valois, MD; Chuck Wurster, MD; Mark Tutschka, MD; Rob Arntfield, MD; Jason Fischer, MD; Mark Tessaro, MD; J. Scott Bomann, DO; Adrian Goudie, MB; Gaby Blecher, MB; Andrée Salter, MB; Michael Rose, MB; Adam Bystrzycki, MB; Shailesh Dass, MB; Owen Doran, MB; Ruth Large, MB; Hugo Poncia, MB; Alistair Murray, MB; Jan Sadewasser, MD; Raoul Breitreutz, MD; Hong Chuen Toh, MB; Arif Alper Cevik, MD; Ang Shiang Hu, MB; Larry Melniker, MD, MS

EXECUTIVE SUMMARY

This executive summary will provide a brief overview of consensus statements on sonography in hypotension and cardiac arrest (SHoC) recommended by the International Federation for Emergency Medicine (IFEM) for use in emergency medicine (EM).

Purpose

As point of care ultrasound (PoCUS) has become an established tool in the initial management of patients with undifferentiated hypotension and during cardiac arrest, the Ultrasound Special Interest Group (USIG) of IFEM was tasked to provide consensus guidance for use in EM that

was designed to be widely implementable internationally, and which was targeted at likely etiologies as well as guiding resuscitation. The protocols were also aimed at minimizing interruption of ongoing resuscitation. A hierarchical model was proposed, to be developed by expert consensus based upon disease incidence, previously published protocols, and the medical literature. A practical checklist was to be developed, along with a standardized approach to the performance of scans based upon a “4 F” approach: *fluid, form, function, filling*.

Consensus approach

We summarized the recorded incidence of PoCUS findings from two international multicentre prospective studies

From *Dalhousie University, Saint John, NB; †Saint John Regional Hospital, Saint John, NB; ‡Sydney Adventist Hospital, Wahroonga, Australia; §University of Sydney, Sydney, Australia; ¶Fraser Health Authority, Surrey, BC; **Advocate Christ Medical Centre, Oak Lawn, IL; ††Royal Victoria Infirmary, Newcastle upon Tyne, UK; ‡‡University of Teesside, Middlesbrough, UK; §§University Hospitals Cleveland Medical Center, Cleveland, OH; ¶¶Case Western Reserve University School of Medicine, Cleveland, OH; **Stellenbosch University, Stellenbosch, South Africa; †††Barts Health NHS Trust, London, UK; and the ‡‡‡Queen Mary University of London; London, UK.

Correspondence to: Dr. Paul Atkinson, International Federation for Emergency Medicine, c/o Carol Reardon, Executive Officer, 34 Jeffcott Street, West Melbourne, VIC 3003, Australia; Email: ifem@acem.org.au

A previous error in this article has been corrected, see 10.1017/cem.2017.31.

Sonography in Hypotension and Cardiac Arrest (SHoC)

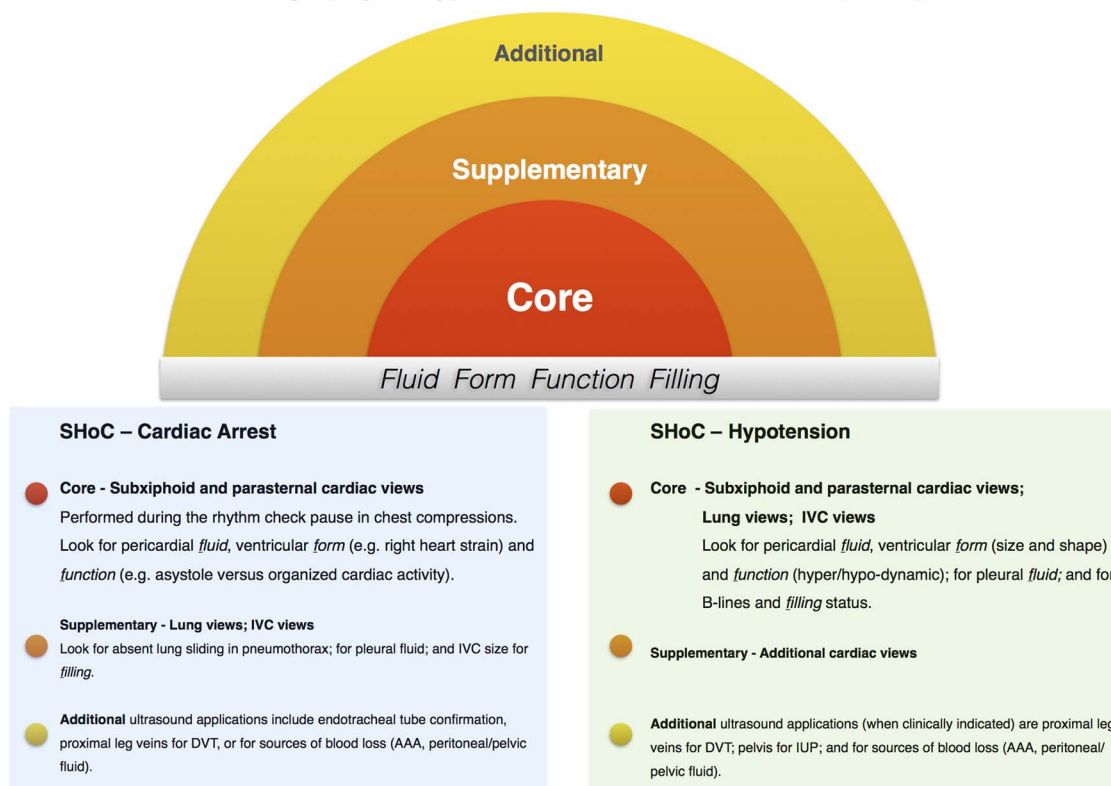


Figure 1. Summary “target style” graphic for the combined SHoC protocols.

in addition to a checklist to guide clinicians incorporating PoCUS into the resuscitation of the arrested patient based on the current literature. Rates of abnormal PoCUS findings were presented to an international expert panel, and using this data we obtained the input of a panel of international experts associated with five professional organizations led by IFEM. Using a modified Delphi approach, after three rounds of the survey, agreement was reached on SHoC-hypotension and SHoC-cardiac arrest protocols comprising core, supplementary, and additional views for each situation, emphasising the importance of clinical probability to guide the priority of scanning. Agreement was also reached on the contents of the checklist.

Recommendations

This international consensus, based on prospectively collected disease incidence, describes two Sonography in Hypotension and Cardiac Arrest (SHoC) protocols, comprising of the stepwise clinical-indication based approach of **Core**, **Supplementary**, and **Additional** PoCUS views.

The *SHoC-hypotension* protocol contains:

Core views focusing on determining the category of shock, whether cardiogenic or non-cardiogenic, and consisting of:

1. Basic cardiac views (primarily the sub-xiphoid window, or parasternal long axis window for pericardial *fluid*, cardiac *form* and ventricular *function*);
2. Lung views for pleural *fluid* and B-lines for *filling* status; and
3. Inferior vena cava (IVC) views for *filling* status.

Supplementary views consisting of other cardiac views; with **Additional** views performed where clinically indicated (e.g., AAA; pelvic; DVT).

The *SHoC-cardiac arrest* protocol contains:

Core views, limited to cardiac windows (primarily sub-xiphoid or parasternal long axis) and must be performed during the rhythm check pause in chest compressions, without causing prolonged interruption in chest compressions. These windows should be used to look for pericardial *fluid*, as well as examining

ventricular *form* (e.g., right heart strain) and *function*, (e.g., asystole versus organized cardiac activity).

Supplementary views consisting of lung (for sliding or fluid) and IVC views; with **Additional** views such as confirmation of endotracheal tube placement or exclusion of aortic aneurysm performed when clinically indicated.

An operational checklist for the use of PoCUS during cardiac arrest is provided and includes the following key steps:

1. Team briefing
2. Preparing the ultrasound machine prior to patient arrival (if time permits)
3. Performing the scan during *breaks* in CPR
4. Reviewing the images *during* CPR

ABSTRACT

Introduction: The International Federation for Emergency Medicine (IFEM) Ultrasound Special Interest Group (USIG) was tasked with development of a hierarchical consensus approach to the use of point of care ultrasound (PoCUS) in patients with hypotension and cardiac arrest.

Methods: The IFEM USIG invited 24 recognized international leaders in PoCUS from emergency medicine and critical care to form an expert panel to develop the sonography in hypotension and cardiac arrest (SHoC) protocol. The panel was provided with reported disease incidence, along with a list of recommended PoCUS views from previously published protocols and guidelines. Using a modified Delphi methodology the panel was tasked with integrating the disease incidence, their clinical experience and their knowledge of the medical literature to evaluate what role each view should play in the proposed SHoC protocol.

Results: Consensus on the SHoC protocols for hypotension and cardiac arrest was reached after three rounds of the modified Delphi process. The final SHoC protocol and operator checklist received over 80% consensus approval. The IFEM-approved final protocol, recommend **Core, Supplementary, and Additional** PoCUS views. SHoC-hypotension core views consist of cardiac, lung, and inferior vena cava (IVC) views, with supplementary cardiac views, and additional views when clinically indicated. Subxiphoid or parasternal cardiac views, minimizing pauses in chest compressions, are recommended as core views for SHoC-cardiac arrest; supplementary views are lung and IVC, with additional views when clinically indicated. Both protocols recommend use of the “4 F” approach: *fluid, form, function, filling*.

Conclusion: An international consensus on sonography in hypotension and cardiac arrest is presented. Future prospective validation is required.

5. Clinical decision making and interventions based on PoCUS findings and reassessment
6. Completion of scanning
7. Post-resuscitation actions

These protocols are focused to direct the clinician to perform views that are clinically indicated, which aims to improve efficiency and reduce the frequency of potentially distracting incidental positive findings that can accompany the current “one size fits all” standard protocols. Figure 1 helps to conceptualize the hierarchical core/supplementary/additional views approach of the SHoC algorithms. This clarifies the essential views for hypotension and cardiac arrest, as well as demonstrating the foundational role that the “4F” approach of *fluid, form, function, and filling* plays in the SHoC protocol.

RÉSUMÉ

Introduction: Le groupe d'intérêt particulier pour l'échographie de l'International Federation for Emergency Medicine (IFEM) s'est vu confier la tâche d'élaborer une démarche hiérarchique consensuelle, relativement à l'utilisation de l'échographie au point de service (EPS) dans les cas d'hypotension ou dans les cas d'arrêt cardiaque.

Méthode: Le groupe d'intérêt a invité 24 sommités en matière d'EPS à l'échelle internationale, provenant des services de médecine d'urgence et de soins intensifs, pour former un groupe d'experts afin d'élaborer un protocole sur l'utilisation de l'échographie dans les cas d'hypotension et dans les cas d'arrêt cardiaque. On a fourni au groupe d'experts l'incidence des maladies concernées ainsi qu'une liste de recommandations sur des prises de vue par EPS, tirées de protocoles et de lignes directrices déjà publiés. Par la suite, on a demandé au groupe d'intégrer l'incidence des maladies concernées, leur expérience clinique et leur connaissance de la documentation médicale en la matière afin d'évaluer, selon une version modifiée de la méthode Delphi, le rôle de chacune des prises de vue dans le protocole SHoC (« Sonography in hypotension and cardiac arrest ») proposé.

Résultats: Le groupe en est arrivé à un consensus, après trois tours de sondage selon la version modifiée de la méthode Delphi, sur le protocole SHoC à appliquer dans les cas d'hypotension et dans les cas d'arrêt cardiaque. La version définitive du protocole ainsi que la liste de vérification des opérateurs ont été approuvées après avoir fait l'objet d'un consensus plus de 80 % des membres. Des prises de vue par EPS, divisées en catégories de **base, supplémentaire et additionnelle**, sont recommandées dans le protocole définitif, approuvé par l'IFEM. Les prises de vue de base dans les cas d'hypotension comprennent des clichés du cœur, des poumons et de la veine cave inférieure (VCI), complétés par

des clichés supplémentaires ou additionnels suivant les indications cliniques. Les prises de vue de base dans les cas d'arrêt cardiaque, recommandées dans le protocole, comprennent des images sous-xiphœidiennes ou parasternales du cœur, qui réduisent au minimum les pauses durant les compressions thoraciques; les clichés supplémentaires comprennent des images des poumons et de la VCI; et les clichés additionnels comprennent d'autres images suivant les indications cliniques. Il est recommandé dans les deux types de cas

visés par le protocole d'appliquer la méthode des « 4 F » : *fluid, form, function, filling*.

Conclusion: Est exposé ici un consensus international sur l'utilisation de l'échographie dans les cas d'hypotension et dans les cas d'arrêt cardiaque. Toutefois, son application exige une validation prospective future.

Keywords: ultrasound, shock, hypotension, life support

INTRODUCTION

The use of point of care ultrasound (PoCUS) as an adjunct to the practice of emergency medicine is now well established internationally. Initially, evidence to support the use of PoCUS came from the management of blunt trauma patients.¹ The scope of practice has expanded as emergency physicians have identified further clinical problems where PoCUS is able to aid diagnosis and guide procedures. Assessment of patients in cardiac arrest and with undifferentiated hypotension are core applications of PoCUS, with various protocols in widespread use in emergency medicine.^{2,3} Previously published protocols are based upon a logical approach to identifying the likely etiology and guiding therapy, but these protocols are frequently based solely on expert opinion and not on the actual incidence of disease, and tend to follow a didactic rigid approach.⁴⁻⁵ Evidence supporting the use of PoCUS in hypotension is limited to diagnostic improvements.⁴⁻⁵ The International Federation for Emergency Medicine (IFEM) Ultrasound Special Interest Group (USIG) was tasked with development of a consensus approach to the use of PoCUS in patients with hypotension and cardiac arrest, taking into account previously published recommendations as well as the reported incidence of disease seen with PoCUS in these clinical scenarios.⁶

PoCUS is an invaluable tool that has potential to clarify essential diagnoses and yield findings that alter management plans.^{4,5} For undifferentiated hypotension, it enables a clinician to assess the category of shock and the response to initial management.

Previously published algorithms fail to adopt a hierarchical approach to their various components,¹⁻³ and most recommend that every patient receives every view, every time. The aim of this consensus was to develop an approach that could be adapted to each clinical scenario.

For cardiac arrest patients, although PoCUS is commonly taught and performed,⁷ to our knowledge no guidelines have yet addressed practical issues such as

operator safety and minimizing delays in cardiopulmonary resuscitation (CPR).

The objectives of this group were to provide consensus-based approaches incorporating reported disease incidence for the use of sonography in hypotension and cardiac arrest (SHoC). The SHoC protocol is presented along with a consensus developed Checklist for clinicians who wish to safely incorporate PoCUS into the resuscitation of the arrested patient.

METHODOLOGY

The IFEM USIG invited 24 recognized international leaders in PoCUS from emergency medicine and critical care to form an expert panel to develop the SHoC protocol. Baseline disease incidence was derived using the reported interim findings of two multicenter prospective studies that examined ultrasound use in undifferentiated hypotension and in cardiac arrest (see Tables 1 and 2).⁶ The panel was also provided with a list of recommended PoCUS views in previously published protocols and guidelines (see Table 3). Using a modified Delphi methodology, the expert panel was tasked with integrating the disease incidence, their clinical experience, and their knowledge of the medical literature to evaluate what role each view should play in the proposed SHoC protocol.⁸

Table 1. International data for incidence of ultrasound findings in undifferentiated hypotension⁶

Sonography in hypotension	
Finding	Frequency
LV dynamic change	43%
IVC abnormalities	27%
Pericardial effusion	16%
Pleural fluid	8%
Peritoneal fluid	5%
AAA	2%

AA = abdominal aortic aneurysm; IV = inferior vena cava; L = left ventricular.

Table 2. Local data for incidence of ultrasound findings in cardiac arrest⁶

Sonography in cardiac arrest	
Finding	Frequency
Contractility abnormality	45%
Abnormal valve function	39%
Pericardial effusion	0%

Table 3. PoCUS views assessed by the expert panel for inclusion in the SHoC protocols:

- 1) Sub-xiphoid or parasternal long axis view
- 2) IVC views
- 3) Additional cardiac views (apical four chamber/parasternal short axis)
- 4) Lung (pleural and pulmonary) views
- 5) Abdomen views for peritoneal fluid
- 6) Aorta views for abdominal aortic aneurysm
- 7) Pelvic views for intrauterine pregnancy
- 8) Lower extremity views for DVT

DVT = deep venous thrombosis; IVC = inferior vena cava; PoCUS = point of care ultrasound; SHoC = sonography in hypotension and cardiac arrest.

Table 4. Hierarchy levels for scans to be included:

- 1) **Core:** To be performed routinely for all patients
- 2) **Supplementary:** To be performed for all patients where this would likely add further information without delaying ongoing critical care
- 3) **Additional:** To be performed when clinically indicated according to the specific clinical circumstances
- 4) **Do Not Include:** Not appropriate for patients with undifferentiated hypotension or cardiac arrest

The panel was asked to assign these views to any of four different priorities in the hierarchical approach, and provide a rationale for their decision (see Table 4). The panel was also asked to structure the protocol in a manner that would be efficient to perform, and would be consistent with current standardized methods for teaching critical care PoCUS (see Table 5).

Reaching consensus

Consensus on the SHoC protocols for hypotension and cardiac arrest was reached after three rounds of the modified Delphi process. Typically, consensus was declared for a given view after that view was assigned to a certain hierarchy with a two-thirds majority at that level or higher (see Appendix 1).

Table 5. Teaching structure for key findings

Cardiac views

- 1) Fluid: Is there a significant pericardial effusion?
- 2) Form: Is the heart small, normal or large? Is the LV larger than the RV?
- 3) Function: Is there vigorous contractility? Are the valves opening?

IVC and lung views

- 4) Filling: Is the IVC dilated and non-collapsing? Is the IVC small and collapsing? Are there multiple B-lines in the lungs bilaterally? Is there pleural fluid?

IVC = inferior vena cava; LV = left ventricular; RV = right ventricular.

In addition to this process, panel members reviewed, modified, and approved an operator Checklist to guide clinicians incorporating PoCUS into the assessment and resuscitation of the arrested patient developed by the Ultrasound Subcommittee of the Australasian College of Emergency Medicine (ACEM), using the described consensus methods. Current recommendations from the International Liaison Committee on Resuscitation and its member organisations were provided to the panel.^{9,10}

The final SHoC protocol and operator Checklist received panel consensus approval (SHoC-hypotension received 82%, and SHoC-cardiac arrest received 83% approval of panel members). The IFEM Board approved the final recommendations.

RECOMMENDATION

1. SHoC-Hypotension

The expert panel reached consensus and recommends the following SHoC-hypotension protocol.

Core views focus on determining the category of shock, whether cardiogenic or non-cardiogenic, and consist of:

1. Basic cardiac views (primarily the subxiphoid window, or parasternal long axis window for pericardial *fluid*, cardiac *form* and ventricular *function*);
2. Lung views for pleural *fluid* and B-lines for *filling* status; and
3. IVC views for filling status.

Supplementary views should be performed if further information is required regarding pericardial fluid or cardiac form or function, and include the additional cardiac views (parasternal short axis and apical views).

SHoC Protocol - Hypotension

Core Views - Should be completed for all patients with undifferentiated hypotension.

1. **Cardiac - Subxiphoid and Parasternal Long Axis**
Look for pericardial fluid, form (size and shape of the chambers) specifically for small ventricular size, or large dilated chambers. Look for right heart strain by assessing the right to left ventricular size ratio. Look at function - is there weak or vigorous ventricular contractility? Are the valves opening to indicate adequate flow?
2. **Lung views - Bilateral anterior and lateral chest views.**
Look for multiple (3 or more per intercostal space) B lines bilaterally indicating interstitial syndrome (such as acute decompensated heart failure), focal B lines indicating possible consolidation, and pleural fluid, again in keeping with heart failure (bilateral) or focal inflammation or haemorrhage (unilateral). Assess for lung sliding to exclude pneumothorax and to confirm lung ventilation if intubated.
3. **IVC views - Subxiphoid or transhepatic view**
Look for overall diameter and respiratory variation in size. In the setting of hypotension, a large IVC with minimal respiratory variation is consistent with high right sided filling pressures, whereas a small IVC with marked respiratory variability is consistent with an under-filled or potentially fluid responsive patient.

Supplementary Views - Should be performed if time permits and more cardiac information is required.

Other cardiac windows (parasternal and apical windows)
Look for further evidence of fluid, and make further assessments of form and function.

Additional Views - Should be performed when clinically indicated according to case specific circumstances

Abdomen-Pelvic Views
Look for peritoneal fluid, if hemorrhage or fluid loss is suspected. This would be indicated in females of child bearing age, especially if there is a positive pregnancy test, in anti-coagulated patients, or in patients with abdominal pain, especially where core views suggest hypovolemia.

Aortic Views
Look for evidence of an abdominal aortic aneurysm. This should be performed in older patients who present with suspicious symptoms or signs such as syncope, abdominal or back pain, or with a history of vascular disease, especially where the core views suggest hypovolemia.

DVT Views
Look for proximal deep vein thrombosis (DVT) in the ileo-femoral veins if veno-thromboembolism is suspected.

(Airway Views)
Consider looking for the double tract sign indicating esophageal intubation, if lung sliding is absent in a ventilated patient.)

Figure 2. Included views in the SHoC-hypotension protocol.

In many clinical scenarios determining a source of hypovolemia or cardiovascular strain is essential. To assist with this, **Additional** views including peritoneal fluid, aorta, pelvic for intrauterine pregnancy (IUP), and proximal leg veins for deep venous thrombosis (DVT) should be performed when indicated. Importantly, although the consensus reached was to include abdomino-pelvic views for peritoneal fluid as an **Additional** (or optional) view, this should be considered **Supplementary** (ranked as more important) for women of childbearing age.

2. SHoC-Cardiac Arrest

The expert panel reached consensus and recommends the following SHoC-cardiac arrest protocol. The agreed protocol focuses on the timing of PoCUS as well as specific clinical questions.

Core views are limited to cardiac views and must be performed during the rhythm check pause in chest compressions, without causing prolonged interruption in chest compressions. The preferred view is the subxiphoid window or the parasternal long axis window if necessary. Either view should be used to look for pericardial *fluid*, as well as examining ventricular *form* (e.g., right heart strain) and *function*, (e.g., asystole versus organized cardiac activity).

Supplementary views include lung views (for absent lung sliding in pneumothorax and for pleural fluid), and IVC views for *filling*.

Additional applications that may assist during cardiac arrest include the use of PoCUS for endotracheal tube confirmation, scanning proximal leg veins for DVT, or looking for sources of blood loss (AAA, peritoneal or pelvic fluid).

These consensus protocols do not specify how findings should direct clinical management. They instead

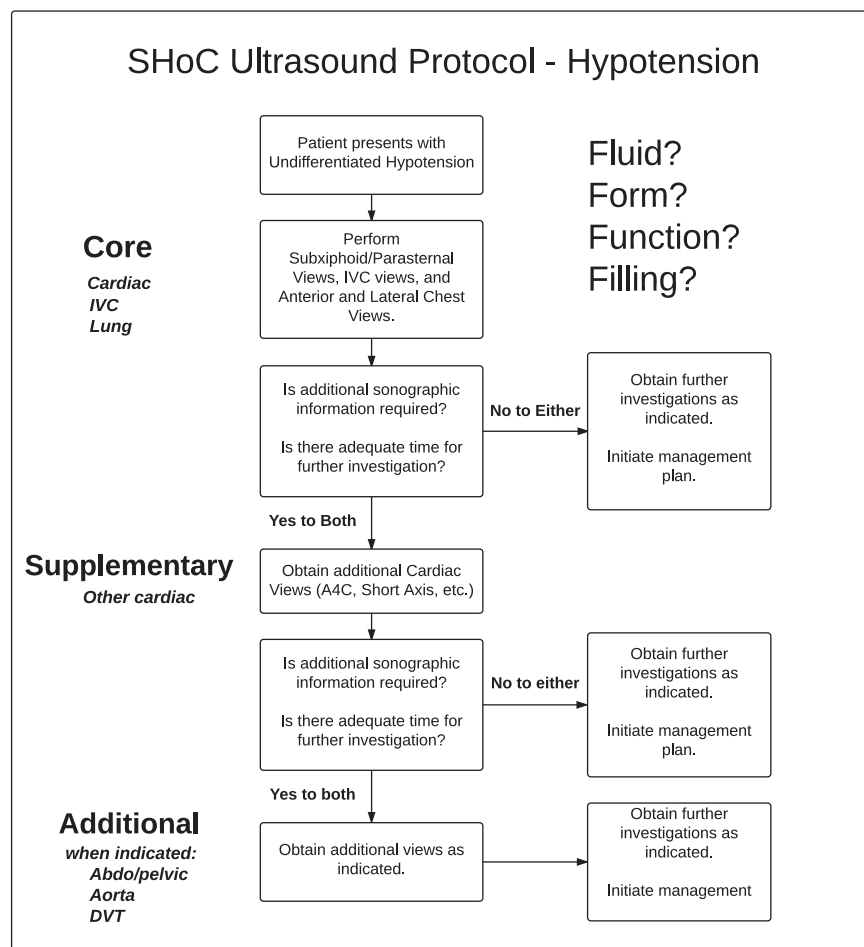


Figure 3. SHoC-hypotension protocol summary.

represent a consensus on the prioritization of scanning for these critically ill patients, based on the likelihood of detection of underlying pathology, and the perceived impact on patient management.

DISCUSSION

PoCUS is an essential tool for the evaluation of many patients in the ED. A “one size fits all” investigation is rarely appropriate for any critically ill ED patient, yet this is how many of the current PoCUS protocols approach patients with undifferentiated hypotension (all patients get all included views, all the time) or cardiac arrest. Examples of commonly recommended, yet rarely positive views are those for peritoneal fluid and for aortic aneurysm. It is likely that, as these views were commonly taught as core emergency ultrasound scans, they have been included in hypotension protocols as a result of familiarity. Our expert panel reached the consensus that, although obtaining peritoneal views to assess for

peritoneal fluid or views for AAA are essential in certain patient categories, the diagnostic yield is low and rarely helpful as a first-line scan. The SHoC protocols’ hierarchical approaches, based on the pre-test probability of disease, are advantageous over current “one size fits all” standards.

In the SHoC-hypotension protocol, all patients first receive a basic cardiac view, such as the subxiphoid or parasternal long axis window to look for pericardial fluid, the form, or size and shape of the cardiac chambers, and the function of the ventricles; next, lung views for evidence of pneumothorax, multiple bilateral B-lines indicating potential pulmonary edema, or pleural effusions consistent with congestive heart failure; and then and an IVC view looking for respiratory variation in size. Together these views should help determine whether the hypotensive patient is likely to be fluid responsive or not; a key initial factor in resuscitation. These views will also exclude clinically obscure pathology such as cardiac tamponade. In patients for

SHoC Protocol - Cardiac Arrest

Ensure that chest compressions are not interrupted to perform PoCUS. Use the rhythm/pulse check break to perform scans (less than 10 seconds interruption to CPR)

Core Views - Should be completed for all patients during cardiac arrest.

1. Cardiac - Subxiphoid or Parasternal Long Axis
 Look for pericardial fluid, form (size and shape of the chambers) specifically for small ventricular size, or large dilated chambers. Look for right heart strain by assessing the right to left ventricular size ratio. Look at function - is there weak or vigorous ventricular contractility? Are the valves opening to indicate adequate flow.

Supplementary Views - Should be performed if time permits and more information is required.

2. Lung views - Bilateral anterior and lateral chest views.
 Assess for lung sliding to exclude pneumothorax, and to confirm adequate bilateral ventilation if intubated. Look for multiple (3 or more per intercostal space) B lines bilaterally indicating interstitial syndrome (such as acute decompensated heart failure), focal B lines indicating possible consolidation, and pleural fluid, again in keeping with heart failure (bilateral) or focal inflammation or hemorrhage (unilateral).

3. IVC views - Subxiphoid or transhepatic view
 Look for overall diameter and respiratory variation in size. In the setting of cardiac arrest, a large IVC with minimal respiratory variation is commonly seen due to the low flow state, whereas a small IVC with marked respiratory (ventilatory) variability is consistent with an under-filled or potentially fluid responsive patient.

Additional Views - Should be performed when clinically indicated according to case specific circumstances

Abdomen-Pelvic Views
 Look for peritoneal fluid, if hemorrhage or fluid loss is suspected. This would be indicated in females of child bearing age, especially if there is a positive pregnancy test, in anti-coagulated patients, or in patients with abdominal pain, especially where core views suggest hypovolemia.

Aortic Views
 Look for evidence of an abdominal aortic aneurysm. This should be performed in older patients who present with suspicious symptoms or signs such as syncope, abdominal or back pain, or with a history of vascular disease, especially where the core views suggest hypovolemia.

DVT Views
 Look for proximal deep vein thrombosis (DVT) in the ileo-femoral veins if veno-thromboembolism is suspected.

Airway Views
 Scan the anterior neck and look for the double tract sign indicating esophageal intubation, if lung sliding is absent in a ventilated patient.

Figure 4. Included views in SHoC-cardiac arrest protocol.

whom a diagnosis is not immediately clear and for whom definitive management would not be delayed, supplementary cardiac views, such as the parasternal short and apical windows, should also be obtained. Additional views are only recommended when clinically indicated to exclude specific suspected pathology.

In the SHoC-cardiac arrest protocol, the focus is to obtain a global view of the heart during the hiatus in chest compressions for a brief rhythm check. The core sub-xiphoid view, or back-up parasternal long axis view, will enable detection of pericardial fluid, as well as a focused assessment for cardiac form and function. The detection of potentially reversible causes of cardiac arrest is essential during the early phases of the management of patients with non-shockable rhythms. Detection of a massively enlarged right ventricle may indicate an underlying pulmonary embolism, whereas

vigorous ventricular contractility may indicate a hypovolemic state. Supplementary views include lung and IVC views. These views will be achievable during established resuscitation or in the peri-arrest or post-resuscitation phase. Bilateral lung sliding confirms adequate ventilation and excludes tension pneumothorax. Multiple B-lines or bilateral pleural effusions may point to congestive heart failure. A small collapsing IVC may confirm a hypovolemic state. A large dilated IVC is a common finding during cardiac arrest. Again, additional views are only recommended when clinically indicated, and must not interrupt ongoing chest compressions, but may assist with procedures such as confirmation of tracheal intubation. The checklist (provided in Appendix 2) may be used with the SHoC-cardiac arrest protocol to guide practitioners in the practical details related to the

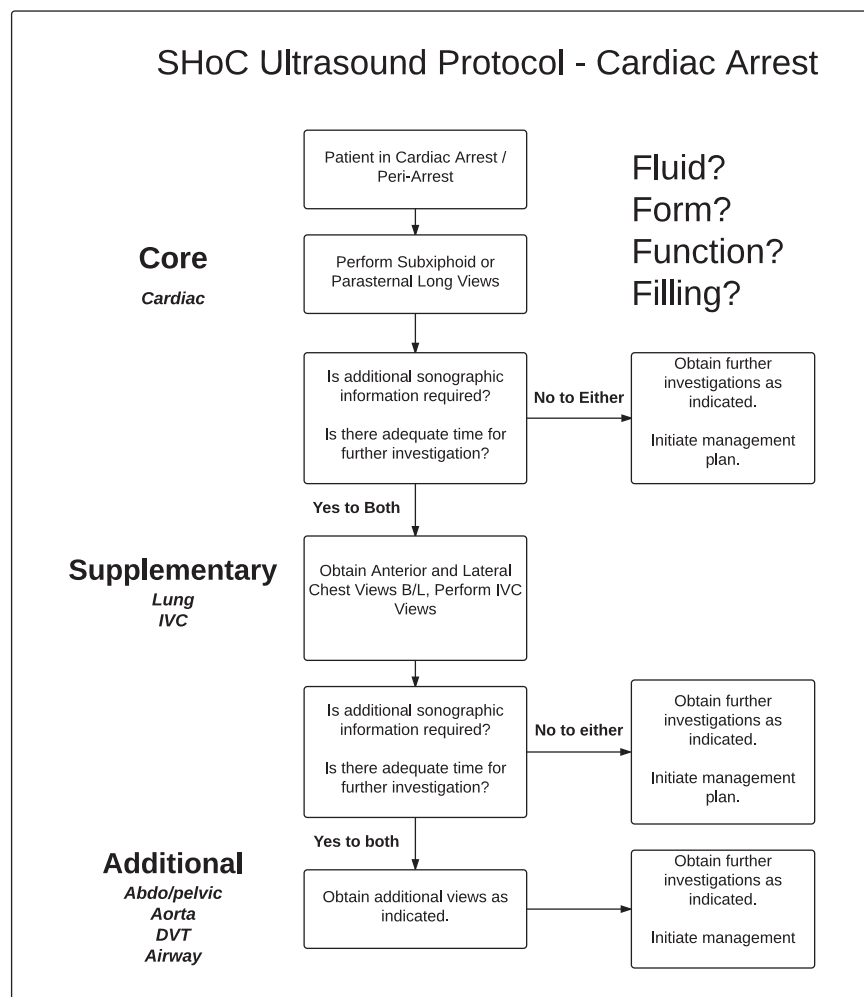


Figure 5. SHoC-cardiac arrest protocol summary.

performance of PoCUS when resuscitating a patient in cardiac arrest.

We believe that a hierarchical approach, based upon established incidence of disease or the estimated likelihood of disease is consistent with the fact that PoCUS should be used as a diagnostic tool, instead of a screening tool. When a scan is performed to assess for an *unexpected* etiology (a screening scan), a positive finding is more likely to be incidental and may distract from the underlying diagnosis. If the same scan is performed for an *expected* etiology (a diagnostic scan), a positive finding is far more likely to be pertinent to the accurate diagnosis. The SHoC protocol is the first PoCUS approach with an international consensus that is focused on diagnostic and resuscitative purposes. These recommendations are derived from expert consensus in an effort to standardize the approach to PoCUS in critically ill patients. Research needs to be

performed to validate this approach, and to show it improves patient outcomes over existing resuscitation protocols. The recommended protocols are depicted in Figures 2-5 and in Appendices 1 and 2.

CONCLUSION

We present an international consensus for the use of sonography in hypotension and cardiac arrest (SHoC) based on prospectively collected disease incidence. The proposed SHoC protocols for hypotension and cardiac arrest, and the cardiac arrest checklist, are stepwise clinical-indication based approaches, incorporating **Core, Supplementary, and Additional** PoCUS views.

Acknowledgements: We are grateful to the following individuals for their time and expertise as members of the expert panel and advisory committees: Paul Atkinson, Justin Bowra, David Lewis,

Rip Gangahar, Mike Lambert, Bob Jarman, Vickie Noble, Hein Lamprecht, Tim Harris, Melanie Stander, Christofer Muhr, Jim Connolly, Romolo Gaspari, Ross Kessler, Chris Raio, Paul Sierzynski, Beatrice Hoffmann, Chau Pham, Michael Woo, Paul Olszynski, Ryan Henneberry, Oron Frenkel, Jordan Chenkin, Greg Hall, Louise Rang, Maxime Valois, Chuck Wurster, Mark Tutschka, Rob Arntfeld, Jason Fischer, Mark Tessaro, J. Scott Bomann, Adrian Goudie, Gaby Blecher, Andrée Salter, Michael Rose, Adam Bystrzycki, Shailesh Dass, Owen Doran, Ruth Large, Hugo Poncia, Alistair Murray, Jan Sadewasser, Raoul Breikreutz, Larry Melniker, Rip Gangahar, Toh Hong Chuen, Arif Alper Cevik, Ang Shiang-Hu, Raoul Breikreutz, Hong Chuen Toh, Arif Alper Cevik, Ang Shiang Hu, and Larry Melniker.

We also wish to thank Ms. Carol Reardon, Dr. Terry Mulligan and Dr. Jim Ducharme of IFEM for their advice on the manuscript.

REFERENCES

- Scalea TM, Rodriguez A, Chiu WC, et al. Focused assessment with sonography for trauma (FAST): results from an international consensus conference. *J Trauma* 1999;46(3):466-72.
- Perera P, Mailhot T, Riley D, et al. The RUSH exam: Rapid Ultrasound in SHock in the evaluation of the critically ill. *Emerg Med Clin North Am* 2010;28(1):29-56.
- Atkinson P, McAuley D, Kendall R, et al. Abdominal and Cardiac Evaluation with Sonography in Shock (ACES): An approach by emergency physicians for the use of ultrasound in the undifferentiated hypotensive patient. *Emerg Med J* 2009;26:87-91.
- Jones AE, Tayal VS, Sullivan DM, et al. Randomized, controlled trial of immediate versus delayed goal-directed ultrasound to identify the cause of nontraumatic hypotension in emergency department patients. *Crit Care Med* 2004;32(8):1703-8.
- Elmer J, Noble VE. An evidence-based approach for integrating bedside ultrasound into routine practice in the assessment of undifferentiated shock. *ICU Director* 2010;1(3):163-74.
- Milne J, Atkinson P, Lewis D, et al. Sonography in Hypotension and Cardiac Arrest (SHoC): Rates of abnormal findings in undifferentiated hypotension and during cardiac arrest as a basis for consensus on a hierarchical point of care ultrasound protocol. *Cureus* 2016;8(4):e564. doi:10.7759/cureus.564.
- Australasian College for Emergency Medicine Policy 61: Policy on Credentialing for Echocardiography in Life Support, accessed 25.07.2016, Available at: <https://www.acem.org.au/getattachment/2cbfee3-dd4e-48fe-9e42-f77d2f145893/Policy-on-Credentialing-for-Echocardiography-in-L.aspx> (accessed September 1, 2016).
- Okoli C, Pawlowski SD. The Delphi method as a research tool: an example, design considerations and applications. *Information & management* 2004;42(1):15-29.
- Soar J, Nolan JP, Böttiger BW, et al. European resuscitation council guidelines for resuscitation 2015: section 3. Adult advanced life support. *Resuscitation* 2015;95:100-47.
- Australian Resuscitation Council Guideline 11.6 - Equipment and Techniques in Adult Advanced Life Support. Available at: <http://resus.org.au/guidelines/> (accessed July 7, 2016).
- Gaspari R, Weekes A, Adhikari S, et al. Emergency department point-of-care ultrasound in out-of-hospital and in-ED cardiac arrest. *Resuscitation* 2016;109:33-9. doi: 10.1016/j.resuscitation.2016.09.018.

APPENDIX 1: RATES OF EXPERT PREFERENCE FOR PRIORITY OF EACH VIEW

View	Priority Selection Rates			
	Core	Supplementary	Additional	Do not include
Sub-xiphoid or parasternal	100%*	0%	0%	0%
IVC	78%	13%	9%	0%
Additional cardiac	9%	65%	26%	0%
Lung	68%	32%	0%	0%
Peritoneal fluid	0%	32%	68%	0%
Aorta	13%	26%	57%	4%
Pelvic views for IUP	0%	13%	78%	9%
Leg views for DVT	0%	9%	83%	9%

*Bold percentages indicate views reaching threshold for inclusion.
IUP = intrauterine pregnancy; IVC = inferior vena cava; DVT = deep vein thrombosis.

APPENDIX 2. ULTRASOUND IN CARDIAC ARREST: CHECKLIST

Preamble

This is a checklist to guide practitioners in the performance of point of care ultrasound (PoCUS) when resuscitating a patient in cardiac arrest. It has been developed by the Ultrasound Subcommittee of the Australasian College for Emergency Medicine (ACEM) and the Ultrasound Curriculum Working Group of the International Federation for Emergency Medicine (IFEM). It incorporates recommendations from International Liaison Committee on Resuscitation (ILCOR) member organisations and the international consensus process on PoCUS in shock and cardiac arrest led by IFEM.

Checklist

Please note that the checklist only applies to patients in cardiac arrest and also that the Advanced (Cardiac) Life

Support (ALS/ACLS) algorithm takes priority at all times. Please also see the **Notes** section for a detailed explanation of the checklist.

1. Team briefing
 - a. Is it likely that PoCUS will alter the outcome of this case?
 - Yes: team leader assigns a team member to perform PoCUS
 - No: continue standard ALS/ACLS
 - b. Safety briefing
 - c. Which side of patient to set up ultrasound machine?
 - d. Scanning team member is to scan and save images during rhythm checks
2. Prepare the machine prior to patient arrival (if time permits)
 - a. Patient details: choose “temporary ID”
 - b. Probe: sector ideal, curved acceptable
 - c. Preset: cardiac ideal, abdominal or “FAST” acceptable
 - d. Initial window (core cardiac): sub-xiphoid ideal, parasternal long-axis acceptable
 - e. Depth (and focus if available) set to 25 cm for adult subcostal, far gain turned up
 - f. Save video clips or cine-loops rather than still images
 - g. Position probe during CPR if possible, to set up your view before break in CPR
3. Perform the scan during breaks in CPR
 - a. Core views (cardiac): fluid, form, function
 - b. Consider Supplementary views: lungs, inferior vena cava (IVC)
 - c. Consider Additional views as clinically indicated
4. Review the images during CPR
5. Clinical decisions and interventions based on PoCUS findings and then reassess.
6. Cease scanning when team leader decides that PoCUS is non-contributory or no longer required.
7. Post-resuscitation

- a. Amend patient details on the US machine, then save exam
- b. Documentation in clinical record
- c. Clean up and debrief

Notes

Team briefing. This can occur prior to ALS/ACLS or at any stage during ALS/ACLS. Although PoCUS may improve outcomes in patients with reversible causes for cardiac arrest (CA), not all clinicians are trained in focused cardiac US and not all cases of CA require PoCUS (e.g., shockable rhythm with return of spontaneous circulation). Safety briefing is crucial: the team member performing the scan will have their hands and the transducer in contact with the patient while the defibrillator is “live”.

Preparing the machine. Ideally this step should have been considered and planned in advance, with the ideal pre-set / cine-loop length, / retrospective loop function programmed by the local ED team. Choose “temporary ID” or enter patient details after resuscitation is completed. Choice of probe / transducer is up to the individual. Sector probe is ideal in adults, curvilinear probe is acceptable, and linear probe (ideally using trapezoid/ “virtual convex” setting) is ideal for infants. If focal zone is available on the machine, set this at 20-25 cm. It is preferable to save video clips/cine-loops rather than still images. When preparing to scan, test whether the machine is saving prospective or retrospective loops by pressing the “save” button. Also consider whether you can find and can review saved loops with the team leader.

Performing the scan and reviewing images. Timing is crucial. Obtain and record images during breaks in CPR, but review images during CPR. Show the loops to the team leader, and try not to distract the rest of the team.

Core views (cardiac):

- *Fluid* in pericardial space suggests pericardial tamponade in the appropriate clinical context. Other signs are generally sought e.g., right ventricular (RV) diastolic collapse, but details are beyond the scope of this document.
- *Form*: a small left ventricle (LV) suggests hypovolemia. A grossly dilated LV suggests chronic cardiac failure. If the RV diameter is greater than that of the LV, this suggests right heart strain (e.g., pulmonary embolus [PE]).

- *Function*: although absence of organised LV activity suggests a poor outcome, it has not been shown to be 100% predictive of futility.¹¹

Supplementary views (lung, IVC). These should be sought only if time permits and additional information required.

- Lungs: if clinical suspicion of tension pneumothorax (TPTX) or endotracheal tube (ETT) misplacement scan the anterior surface of each hemithorax; consider additional lung views if clinical suspicion of other pathology. Note that in both TPTX and unventilated lung, lung sliding is absent on US. Differentiating requires a combination of clinical assessment (e.g., how far down is ETT? Is there any reason for PTX in this patient? Is the patient difficult to ventilate?) and US features (presence of lung pulse or any comets, B-lines will rule out PTX on that side). It is not recommended to seek the "lung point" sign as this only present in smaller PTX and will be

absent in both unventilated lung and TPTX. If there is still doubt, either or both finger thoracostomy or ETT withdrawal may be considered at the discretion of the team leader.

- Inferior vena cava (IVC): a large IVC with minimal respiratory variation is usual in cardiac arrest whereas a small IVC with marked respiratory (ventilatory) variability suggests fluid-responsive patient.

Additional views. These should be performed when clinically indicated according to the specific circumstances of the case.

- Intraperitoneal fluid (e.g., clinical suspicion of ruptured ectopic pregnancy)
- Abdominal aortic aneurysm (AAA) may be an incidental finding in the arrested patient. Once again, clinical context is paramount.
- Proximal deep venous thrombosis (DVT) (if suspicion of PE and inconclusive cardiac views)