

Images

Adult Hirschsprung's disease

Joseph P. Martinez, MD

A 43-year-old schizophrenic man presented to the emergency department, complaining of abdominal distention and constipation. He was markedly distended without evidence of peritoneal signs. Multidetector computed tomography demonstrated massive distention of the sigmoid colon up to 20 cm in diameter (Figures 1 and 2) without evidence of perforation.

DIAGNOSIS

Hirschsprung's disease. Named for the Danish pediatrician who described the disease in 1887,¹ Hirschsprung's disease (congenital aganglionic megacolon) is caused by the failure of neural crest cells to migrate completely during development. This migration failure leads to an aganglionic segment of colon that is unable to relax.

Hirschsprung's disease is the most common cause of neonatal intestinal obstructions² and is typically diagnosed early. Patients with short or ultrashort segment disease may not be diagnosed until childhood, and they may occasionally present as adults. The typical presentation in adults is that of a patient with a lifelong history of severe constipation, which he or she has successfully managed with laxatives and enemas. The patient may seek medical attention due to rapidly worsening abdominal distention and the inability to relieve the constipation, despite using the traditional methods. The mortality rate of Hirschsprung's disease in adults is exceedingly low. However, it occasionally leads to sigmoid volvulus, in which case the mortality rate can be approximately 15%.³ These patients often present with more acute signs of intestinal obstruction, and they may appear more toxic if the volvulus has progressed to bowel ischemia. The diagnosis

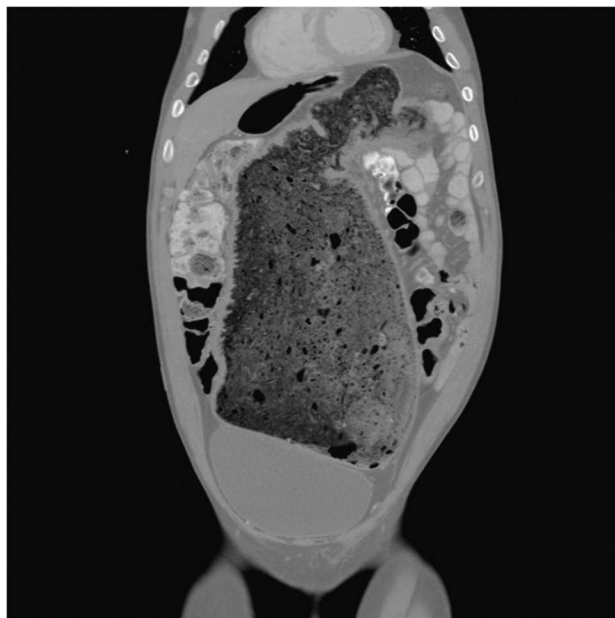


Figure 1. Coronal image of distended sigmoid colon.

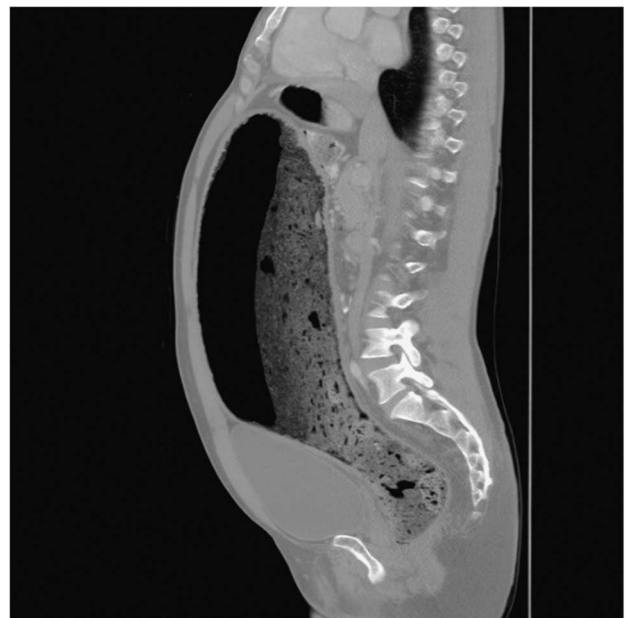

Figure 2. Sagittal image of distended sigmoid colon.

From the Department of Emergency Medicine, University of Maryland School of Medicine, Baltimore, MD.

Correspondence to: Dr. Joseph P. Martinez, Department of Emergency Medicine, University of Maryland School of Medicine, 655 West Baltimore Street, Baltimore, MD, 21201; Email: jmartinez@som.umaryland.edu

of Hirschsprung's disease may be suggested by a plain radiograph or computed tomography, with the definitive diagnosis being made by rectal biopsy. Barium enema, which often is diagnostic in neonates, may be negative in adults due to the ultrashort segment of bowel involved.⁴

The 43-year-old schizophrenic patient related a long history of constipation. On direct questioning, he recalled being diagnosed with Hirschsprung's disease as a child, but his parents never brought him for a follow-up. We admitted the patient to the surgical service, where he showed no improvement with conservative treatment, including intravenous fluid hydration and rectal tube decompression. He underwent a sigmoid colectomy with end colostomy and had an uneventful recovery.

Keywords: Hirschsprung's Disease, megacolon, intestinal obstruction

Competing interests: None declared.

REFERENCES

1. Hirschsprung H. Struhltragheit neugeborener in folge von dilatation and hypertrophic des colons. *Jahrb Kinderb* 1887;27:1-3.
2. Skinner MA. Hirschsprung's disease. *Curr Probl Surg* 1996; 389-460.
3. Tan FLS, Tan YM, Heah SM, Seow-Choen F. Adult Hirschsprung's disease presenting as sigmoid volvulus: a case report and review of literature. *Tech Coloproctol* 2006;10:245-8.
4. Miyamoto M, Egami K, Maeda S, et al. Hirschsprung's disease in adults: report of a case and review of the literature. *J Nippon Med Sch* 2005;72(2):113-20.