EM Advances

Chest compressions do not disrupt the seal created by the laryngeal mask airway during positive pressure ventilation: a preliminary porcine study

Jestin N. Carlson, MD, MSc*†; Brian P. Suffoletto, MD*; David D. Salcido, MPH*; Eric S. Logue, BS*; James J. Menegazzi, PhD*

ABSTRACT

Objective: Pulmonary aspiration of gastric contents occurs 20 to 30% of the time during cardiopulmonary resuscitation (CPR) of cardiac arrest due to loss of protective airway reflexes, pressure changes generated during CPR, and positive pressure ventilation (PPV). Although the American Heart Association has recommended the laryngeal mask airway (LMA) as an acceptable alternative airway for use by emergency medical service personnel, concerns over the capacity of the device to protect from pulmonary aspiration remain. We sought to determine the occurrence of aspiration after LMA placement, CPR, and PPV.

Methods: We inserted a size 4 LMA, modified so that a vacuum catheter could be advanced past the LMA diaphragm, into the hypopharynx of 16 consecutive postexperimental mixed-breed domestic swine. Fifteen millilitres of heparinized blood was instilled into the oropharynx. Chest compressions were performed for 60 seconds with asynchronous ventilation via a mechanical ventilator. We then suctioned through the LMA for 1 minute. The catheter was removed and inspected for signs of blood. The LMA cuff was deflated, removed, and inspected for signs of blood.

Results: None of 16 animals (95% CI 0–17%) had a positive test for the presence of blood in both the vacuum catheter and the intima of the LMA diaphragm.

Conclusions: In this swine model of regurgitation after LMA placement, there were no cases with evidence of blood beyond the seal created by the LMA cuff. Future studies are needed to determine the frequency of pulmonary aspiration after LMA placement during CPR and PPV in the clinical setting.

RÉSUMÉ

Objectif: Il y a passage du contenu gastrique dans les poumons dans 20 à 30% des cas de réanimation cardiorespiratoire (RCR) effectuée pour un arrêt cardiaque, en raison de la perte des réflexes de protection des voies aériennes, des variations de pression causées par les manœuvres de RCR et de la ventilation en pression positive (VPP). Bien que l'American Heart Association ait recommandé le masque laryngé (ML) comme dispositif de rechange acceptable en vue de la protection des voies aériennes, à utiliser par le personnel des services médicaux d'urgence, il subsiste toujours des doutes quant à la capacité du dispositif à éviter les régurgitations dans les poumons. L'étude visait à déterminer la fréquence des régurgitations dans les poumons après la pose d'un ML, durant les manœuvres de RCR et la VPP.

Méthode: Un ML de taille 4, modifié, a été posé de manière à glisser la sonde d'aspiration au-delà de la membrane du ML, dans l'hypopharynx, chez 16 porcs domestiques, hybrides, postexpérimentaux, consécutifs. Quinze millilitres de sang hépariné ont été instillés dans l'oropharynx, puis des compressions thoraciques ont été effectuées pendant 60 secondes en ventilation asynchrone à l'aide d'un ventilateur mécanique. Il y a eu ensuite aspiration trachéale, par l'intermédiaire du ML, pendant 1 minute. La sonde a été retirée, puis examinée à la recherche de traces de sang; le ballonnet du ML a été dégonflé, retiré, et examiné à la recherche de traces de sang.

Résultats: Aucun résultat positif n'a été enregistré, chez les 16 animaux en question (IC à 95%: 0–17%), à l'égard de la présence de sang dans la sonde d'aspiration et sur la face interne de la membrane du ML.

Conclusions: Dans le modèle porcin, ici étudié, de régurgitation après la pose d'un ML, il n'y a eu aucun cas de présence de sang au-delà de la ligne d'étanchéité formée par le coussinet du ML. Toutefois, il faudrait mener d'autres études afin de déterminer la fréquence des régurgitations dans les poumons, après la pose d'un ML, durant les manœuvres de RCR et la VPP, en milieu clinique.

From the *Department of Emergency Medicine, University of Pittsburgh, Pittsburgh, PA, and †Department of Medicine, Division of Emergency Medicine, Saint Vincent Medical Center, Erie, PA.

Presented at National Association of EMS Physicians Annual Meeting, Phoenix, AZ, 2009.

Correspondence to: Dr. Jestin Carlson, Department of Emergency Medicine, University of Pittsburgh, 3600 Forbes Avenue, Suite 400A, Iroquois Bldg, Pittsburgh, PA 15213; carlsonjn@upmc.edu.

This article has been peer reviewed.

© Canadian Association of Emergency Physicians *CJEM* 2014;16(5):378-382 DOI 10.2310/8000.2014.141029

Keywords: cardiopulmonary resuscitation, laryngeal mask airway, positive pressure ventilation

Endotracheal intubation in the prehospital setting is challenging, and success rates vary significantly.[1–3] Complications with intubation and intubation failures have spurred a debate regarding the safety profile of prehospital endotracheal intubation in various patient populations, including out-of-hospital cardiac arrest (OOHCA). Prolonged interruptions in cardiopulmonary resuscitation (CPR) for intubation in OOHCA patients significantly decrease the chances of survival.[4–8] These findings have led to a recent advocacy for the use of alternative airways in the prehospital setting, including the use of the laryngeal mask airway (LMA).[9]

The LMA is a supraglottic device that can be blindly inserted and has a cuff that inflates around the posterior pharynx. It is the primary prehospital airway device in several countries and can rapidly be placed with success rates similar to intubation.[10–12] The LMA provides ventilation equal to other alternative airway devices used in the prehospital setting, and when used as the primary airway device, it results in a lower incidence of regurgitation than bag-valve-mask ventilation or intubation during CPR.[13,14] Aspiration occurs in over 50% of prehospital patients where intubation is attempted and is associated with increased morbidity and mortality.[15,16]

Pulmonary aspiration of gastric contents occurs in 30% of cardiac arrest patients during CPR due to loss of protective airway reflexes and intrathoracic and intra-abdominal pressure changes generated during CPR and positive pressure ventilation (PPV).[17,18] Even though the American Heart Association has recommended the LMA as an acceptable alternative airway for use by emergency medical service (EMS) personnel, concerns over the capacity of the device to prevent pulmonary aspiration remain, especially during CRP and PPV. Previous studies have detailed the incidence of regurgitation associated with LMA use during CPR but not aspiration.[14] Other studies have detailed the incidence of aspiration associated with PPV but not while performing CPR.[14,15] We sought to determine the frequency of aspiration after LMA placement, CPR, and PPV.

METHODS

The study was approved by the University of Pittsburgh Institutional Animal Care and Use Committee. Sixteen postexperimental,[19] mixed-breed, domestic swine of either sex (mean mass 25.7 ± 1.4 kg) with unaltered airways were included in this study. Ventricular fibrillation was induced by delivering a 3-second, 60 Hz, 100 mA alternating current across the chest. Swine had their airways secured with a standard size 4 LMA (LMA North America, San Diego, CA) within 2 minutes of arrest. The LMA was modified by removing the central section of the internal diaphragm to allow passage of a suction catheter through the diaphragm (Figure 1). The modified LMA was then placed in the hypopharynx with the cuff inflated with 30 cc of air. Placement was confirmed via capnography and visualization of chest rise. Neither sedation nor paralytics were used, and all swine had fasted for over 8 hours prior to the experiment, consistent with previous swine models of cardiac arrest.[19]

Heparinized blood, to prevent clotting, was instilled in the posterior pharynx, cephalad to the cuff of the LMA to simulate regurgitation. We used 15 mL to allow for ease of identification by the investigators without completely filling the oropharynx. A suction catheter was advanced into the lumen of the LMA, 4 cm distal to the diaphragm, allowing it to rest within the trachea. This allowed for a noninvasive method of detecting blood as opposed to transtracheal methods, which could potentially introduce blood into the airway. Suction was applied for

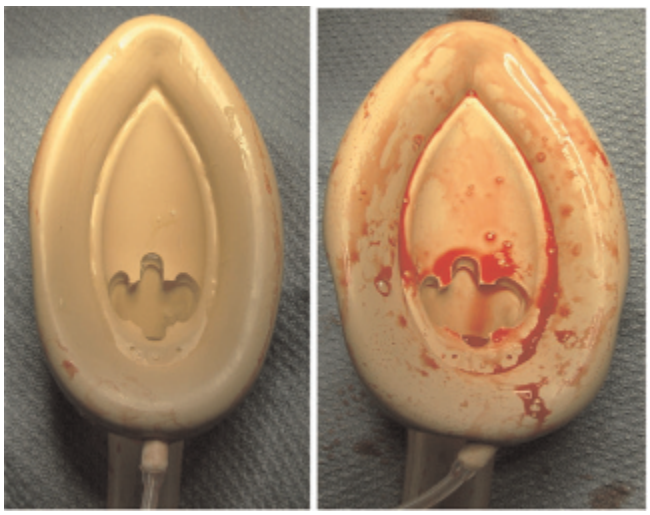

Figure 1. Modified laryngeal mask airway with the bars of the internal diaphragm removed to allow passage of a suction catheter down the lumen, through the diaphragm. The figure on the left shows the inner cuff without blood (negative). The figure on the right shows the inner cuff with blood (positive).

1 minute, and then the catheter was removed and inspected for signs of blood as the baseline. Five 1-second positive pressure breaths (tidal volume 15 cc/kg) were administered via a mechanical ventilator. Chest compressions were performed by a LUCAS mechanical chest compression device (Jolife, Lund, Sweden) at a rate of 100 per minute, a depth of 5 cm in the anteroposterior position, and a duty cycle of 50% while the ventilator delivered asynchronous ventilations at a rate of 12 breaths per minute (Table 1). When regurgitation and emesis occur, they occur in 47% of cases within the first few minutes after cardiac arrest; therefore, CPR was performed for 60 seconds.[14,15]

The suction catheter was reinserted to the same depth, and suction was applied for 1 minute. The catheter was removed and inspected for signs of blood. The LMA cuff was then deflated and removed, and the inner cuff was inspected for signs of blood (see Figure 1). In a validation cohort of four animals, the LMA was reinserted, a cricothyroidotomy was performed, and 5 mL of blood was instilled directly into the trachea to simulate aspiration in this simple model (blood in the trachea). CPR was then repeated as before with accompanying mechanical ventilation. After 1 minute, the LMA was removed and inspected for signs of blood. The presence or absence of blood on the inner cuff, indicating the potential for aspiration, was ascertained and recorded by two investigators (J.J.M., B.P.S.): positive if present, negative if absent (see Figure 1). The study timeline is shown in Figure 2. Airway pressures were not measured in this study. *Stata* version 9 (Statacorp, College Station, TX) was used to calculate 95% confidence intervals for the percentage of positive tests, representing pulmonary aspiration. The data were retrieved in August and September 2010.

Table 1. List of controlled covariates

Covariate	Covariate settings
Induction of ventricular fibrillation	3 seconds 60 Hz 100 mA Alternating current across the chest
CPR	LUCAS mechanical chest compression device 100/min 5 cm depth anteroposterior position Duty cycle 50%
Airway placement	Size 4 LMA Placed within 2 min of induced cardiac arrest
Ventilator settings	Tidal volume 15 cc/kg 12 breaths/min (asynchronous)
Heparin instillation	15 mL in the posterior oropharynx

CPR = cardiopulmonary resuscitation; LMA = largyneal mask airway.

RESULTS

None of the 16 swine showed any visible tracheal aspirate (blood) at baseline or following CPR/PPV (95% CI 0–17%). However, there was visible tracheal aspirate (blood) in all four swine in the validation cohort. There was 100% agreement between the two investigators who evaluated for aspiration independently.

DISCUSSION

With the recent advocacy for the use of alternative airways in the prehospital setting, specifically OOHCA, there is concern over the potential for aspiration with the use of these devices. Stone and colleagues found the rate of regurgitation during CPR and PPV with LMA use to be 3% but did not document the incidence of aspiration accompanying regurgitation.[14] We identified no signs (95% CI 0–17) suggesting aspiration from the oropharynx when the LMA was used in a swine regurgitation model of PPV and CPR, although the sample size was limited.

Our study has several limitations. Although the swine model has been shown to closely resemble human anatomy and as such is used to teach various techniques, including endotracheal intubation,[20] the effectiveness of the LMA in the swine airway may vary from that of humans due to subtle differences in airway anatomy and will require further validation in human models. We performed this study in postexperimental swine to gain as much information as possible from these animals prior to their sacrifice.[19] These animals had fasted for 8 hours for the previous experiment, which also may not reflect human cases of OOHCA. Under certain conditions, there may also be aspiration of stomach contents from the upper esophagus into the trachea during CPR and PPV, and this was not tested in this study. The act of vomiting, which applies significant forces to the posterior pharynx, may dislodge the LMA and produce different results when tested in the clinical setting. Furthermore, although we performed 60 seconds of CPR with PPV, the risk of aspiration may increase with longer durations of CPR

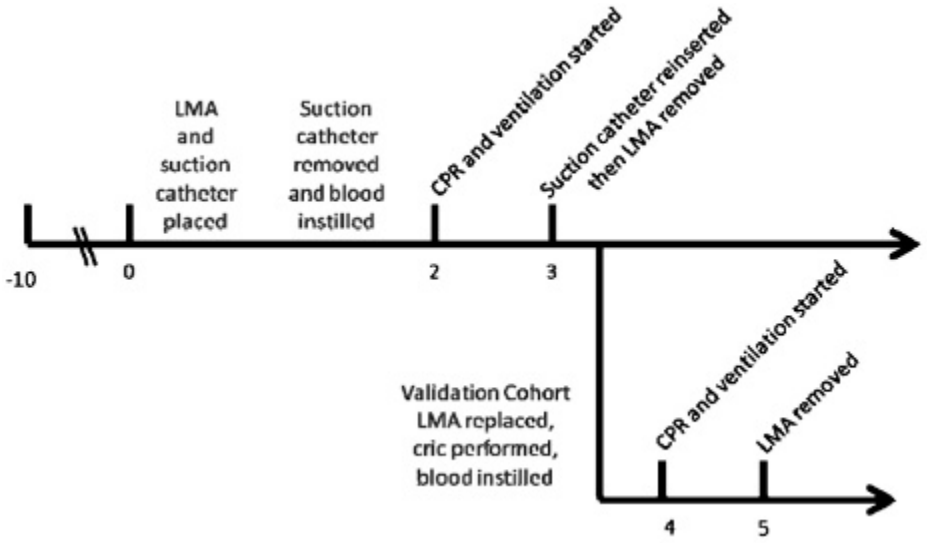

Figure 2. Experimental timeline in minutes. CPR = cardiopulmonary resuscitation, cric = cricothyroidotomy; LMA = laryngeal mask airway.

with PPV. Previous studies have found that regurgitation and emesis most often occur within the first 2 to 3 minutes after arrest, often before providers arrive and rarely after placement of the LMA.[14,15] There may continue to be ongoing risk of aspiration with longer resuscitation efforts, and further efforts will be needed to evaluate the risk of aspiration with resuscitations of various length. Furthermore, different methods of ventilation (e.g., synchronous versus asynchronous ventilations, provider with bag-valve versus ventilator-delivered breaths) may alter rates of aspiration and will require further study.

We did not evaluate diverse airway anatomy such as the traumatic airway, whether pre-existing or iatrogenic. Further study will be needed to evaluate the performance of the LMA under these circumstances. We evaluated only for the presence of gross aspiration. Although microaspiration may have occurred, its significance is unclear, and no cases of gross aspiration were noted. We did not perform blinded outcome assessment; however, the investigators did evaluate each LMA independently to help reduce bias. Cuff pressure was also not measured either at the beginning or during our study. The cuff was inflated as per the manufacturer's recommendations, as would be done in the OOHCA setting, but variability in cuff pressure throughout the experiment was a possibility.

CONCLUSION

In this swine model of regurgitation after LMA placement, there were no cases (95% CI 0–17%) with evidence of pulmonary aspiration or blood beyond the seal created by the LMA cuff following PPV and CPR. Future studies are needed to determine the frequency of pulmonary aspiration after LMA placement during CPR and PPV in the clinical setting.

Competing interests: The LUCAS device that was used in this study was loaned to Dr. Menegazzi by Jolife. Neither Dr. Menegazzi nor any of the other investigators have any financial interest in Jolife. Jolife had no input into the design, conduct, or interpretation of this study. Dr. Menegazzi was supported in part by grant 5RO1HL080480-04 from the National Heart, Lung, and Blood Institute. Dr. Suffoletto was supported by the Society for Academic Emergency Medicine Institutional Training Grant.

REFERENCES

1. Hubble MW, Brown L, Wilfong DA, et al. A meta-analysis of prehospital airway control techniques part I: orotracheal and nasotracheal intubation success rates. *Prehosp Emerg Care* 2010;14:377-401, doi:10.3109/10903121003790173.
2. Wang HE, Yealy DM. How many attempts are required to accomplish out-of-hospital endotracheal intubation? *Acad Emerg Med* 2006;13:372-7, doi:10.1111/j.1553-2712.2006.tb00311.x.
3. Bushra JS, McNeil B, Wald DA, et al. A comparison of trauma intubations managed by anesthesiologists and emergency physicians. *Acad Emerg Med* 2004;11:66-70, doi:10.1197/j.aem.2003.08.013.
4. Wang HE, Simeone SJ, Weaver MD, et al. Interruptions in cardiopulmonary resuscitation from paramedic endotracheal intubation. *Ann Emerg Med* 2009;54:645-52 e1, doi:10.1016/j.annemergmed.2009.05.024.
5. Vaillancourt C, Everson-Stewart S, Christenson J, et al. The impact of increased chest compression fraction on return of spontaneous circulation for out-of-hospital cardiac arrest

patients not in ventricular fibrillation. *Resuscitation* 2011;82:1501-7, doi:10.1016/j.resuscitation.2011.07.011.

6. Christenson J, Andrusiek D, Everson-Stewart S, et al. Chest compression fraction determines survival in patients with out-of-hospital ventricular fibrillation. *Circulation* 2009;120:1241-7, doi:10.1161/CIRCULATIONAHA.109.852202.
7. Berg RA, Sanders AB, Kern KB, et al. Adverse hemodynamic effects of interrupting chest compressions for rescue breathing during cardiopulmonary resuscitation for ventricular fibrillation cardiac arrest. *Circulation* 2001;104:2465-70, doi:10.1161/hc4501.098926.
8. Sanders AB, Kern KB, Berg RA, et al. Survival and neurologic outcome after cardiopulmonary resuscitation with four different chest compression-ventilation ratios. *Ann Emerg Med* 2002;40:553-62, doi:10.1067/mem.2002.129507.
9. Berg RA, Hemphill R, Abella BS, et al. Part 5: adult basic life support: 2010 American Heart Association Guidelines for Cardiopulmonary Resuscitation and Emergency Cardiovascular Care. *Circulation* 2010;122(18 Suppl 3):S685-705, doi:10.1161/CIRCULATIONAHA.110.970939.
10. Guyette FX, Greenwood MJ, Neubecker D, et al. Alternate airways in the prehospital setting (resource document to NAEMSP position statement). *Prehosp Emerg Care* 2007;11:56-61, doi:10.1080/10903120601021150.
11. Guyette FX, Roth KR, LaCovey DC, et al. Feasibility of laryngeal mask airway use by prehospital personnel in simulated pediatric respiratory arrest. *Prehosp Emerg Care* 2007;11:245-9, doi:10.1080/10903120701205273.
12. Wang HE, Mann NC, Mears G, et al. Out-of-hospital airway management in the United States. *Resuscitation* 2011;82:378-85, doi:10.1016/j.resuscitation.2010.12.014.
13. Rumball CJ, MacDonald D. The PTL, Combitube, laryngeal mask, and oral airway: a randomized prehospital comparative study of ventilatory device effectiveness and cost-effectiveness in 470 cases of cardiorespiratory arrest. *Prehosp Emerg Care* 1997;1:1-10, doi:10.1080/10903129708958776.
14. Stone BJ, Chantler PJ, Baskett PJ. The incidence of regurgitation during cardiopulmonary resuscitation: a comparison between the bag valve mask and laryngeal mask airway. *Resuscitation* 1998;38:3-6, doi:10.1016/S0300-9572(98)00068-9.
15. Brimacombe JR, Berry A. The incidence of aspiration associated with the laryngeal mask airway: a meta-analysis of published literature. *J Clin Anesth* 1995;7:297-305, doi:10.1016/0952-8180(95)00026-E.
16. Ufberg JW, Bushra JS, Karras DJ, et al. Aspiration of gastric contents: association with prehospital intubation. *Am J Emerg Med* 2005;23:379-82, doi:10.1016/j.ajem.2005.02.005.
17. Virkkunen I, Kujala S, Ryynanen S, et al. Bystander mouth-to-mouth ventilation and regurgitation during cardiopulmonary resuscitation. *J Intern Med* 2006;260:39-42, doi:10.1111/j.1365-2796.2006.01664.x.
18. Simons RW, Rea TD, Becker LJ, et al. The incidence and significance of emesis associated with out-of-hospital cardiac arrest. *Resuscitation* 2007;74:427-31, doi:10.1016/j.resuscitation.2007.01.038.
19. Suffoletto BP, Salcido DD, Logue ES, et al. Ethyl pyruvate enhances intra-resuscitation hemodynamics in prolonged ventricular fibrillation arrest. *Resuscitation* 2009;80:1411-6, doi:10.1016/j.resuscitation.2009.08.014.
20. Ettrup KS, Glud AN, Orlowski D, et al. Basic surgical techniques in the Gottingen minipig: intubation, bladder catheterization, femoral vessel catheterization, and transcardial perfusion. *J Vis Exp* 2011;(52). pii:2652, doi:10.3791/2652.