Diagnostic Challenge

A diabetic patient in septic shock

Nejmeddine Affes, MD;* Atef Bahloul, MD;† Youssef Dammek, MD;* Hatem Kallel, MD;‡ Rafik Mzali, MD;* Mohamed Issam Beyrouti, MD*

CASE PRESENTATION

A 45-year-old man with schizophrenia and diabetes who had been taking oral hypoglycemics for 12 years presented to the emergency department in septic shock. On examination, he was obnubilated, with an oral temperature of 39.5°C, tachycardia and diffuse abdominal tenderness. Laboratory findings were remarkable for leukocytosis, with a white blood cell count of 23 $\times 10^9$/L; a serum glucose level of 44 mmol/L; a serum creatinine level of 300 μmol/L; and both glucose and ketones in the urine. Bedside ultrasonography showed a slack gallbladder with a 5-mm thick laminated wall. On bladder catheterization, microscopic hematuria, pyuria and pneumaturia were noted. An abdominal CT scan was obtained (Fig. 1).

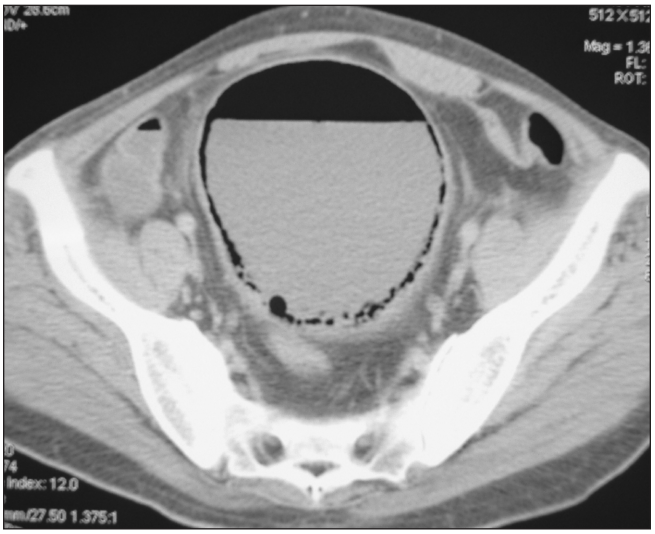

Fig. 1. Abdominal CT scan of a 45-year-old man with septic shock.

QUESTION

What is the most likely diagnosis?
a) acalculous cholecystitis
b) perinephric abscess
c) emphysematous cystitis
d) enterovesical fistula

For the answer to this challenge see page 540.

From the Departments of *General Surgery and †Urology and the ‡Emergency Department, Habib Bourguiba Hospital, Sfax, Tunisia

Submitted Jan. 12, 2009; Accepted Oct. 2, 2009

This article has been peer reviewed.

CJEM 2010;12(6):527