Bilateral subacute-chronic subdural hematomas

A 73-year-old man with no past medical history of note presented to the emergency room with progressive cognitive impairment and difficulty walking. He had been well until 4 weeks earlier, when he suffered a fall with minor head trauma. In the following weeks, he experienced additional falls, again suffering minor head trauma. On admission, physical examination revealed mental slowness and paresis of 4 out of 5 of his left extremities; and he had no papilledema. Blood chemistry, hematology and coagulation laboratory data were normal. Cranial CT (Fig. 1) showed crescentic hypo-isodense collections in both hemispheres, the right collection being larger, with midline shift.

According to the CT characteristics, this patient was suffering from bilateral subdural hematomas of different ages. A bilateral presence is infrequent and has been described in cases of head trauma, ruptured cerebral artery aneurysm, cerebral neoplasms, lumbar puncture, spinal anesthesia, lumbar diskectomy, anticoagulant therapy, coagulopathy and thrombocytopenia, among others.[1,2] Recurrent trauma at different times explains the coexistence of both subacute and chronic hemorrhages.

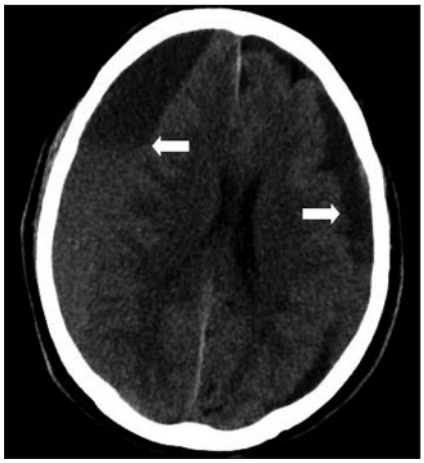

Fig. 1. Cranial CT showing crescentic hypoisodense collections (arrows) in both hemispheres, the right collection being larger with midline shift.

José María Calvo-Romero
Internal Medicine Service
Hospital Ciudad de Coria
Coria (Cáceres), Spain

References

1. Sadrolhefazi A, Bloomfield SM. Interhemispheric and bilateral chronic subdural hematoma. Neurosurg Clin N Am 2000;11:455-63.
2. Bruno MC, Santangelo M, Panagiotopoulos K, et al. Bilateral chronic subdural hematoma associated with meningioma. Case report and review of the literature. J Neurosurg Sci 2003;47: 215-27.